A neonate born to a 26-year-old woman is evaluated in the newborn nursery. The neonate was delivered vaginally at 38 weeks gestation, and Apgar scores were 8 and 9 at 1 and 5 minutes, respectively. Physical examination shows hydrocephalus, jaundice, and hepatosplenomegaly. Funduscopic examination reveals retinal exudates and scarring. Histopathological evaluation of the placenta shows infiltration of lymphocytes, plasma cells, and macrophages, and there are numerous intracellular, crescent-shaped organisms with a central nucleus. Which of the following would have been most effective in preventing this patient's current condition?

A. Adequate maternal preconception immunization

B. Avoidance of undercooked meat consumption

C. Consumption of pasteurized milk products

D. Strict avoidance of mosquitoes during pregnancy

E. Use of prophylactic penicillin during labor

Submit

A neonate born to a 26-year-old woman is evaluated in the newborn nursery. The neonate was delivered vaginally at 38 weeks gestation, and Apgar scores were 8 and 9 at 1 and 5 minutes, respectively. Physical examination shows hydrocephalus, jaundice, and hepatosplenomegaly. Funduscopic examination reveals retinal exudates and scarring. Histopathological evaluation of the placenta shows infiltration of lymphocytes, plasma cells, and macrophages, and there are numerous intracellular, crescent-shaped organisms with a central nucleus. Which of the following would have been most effective in preventing this patient's current condition?

A. Adequate maternal preconception immunization (19%)
✓ B. Avoidance of undercooked meat consumption (46%)
C. Consumption of pasteurized milk products (9%)
D. Strict avoidance of mosquitoes during pregnancy (18%)
E. Use of prophylactic penicillin during labor (6%)

Omitted
Correct answer
B

46%
Answered correctly

08 secs
Time Spent

04/07/2020
Last Updated

Explanation

This neonate with retinal lesions (chorioretinitis), hydrocephalus, and a placenta infiltrated with crescent-shaped organisms likely has **congenital toxoplasmosis**, an infection caused by the **intracellular parasite** *Toxoplasma gondii*. Humans typically acquire the infection due to:

- Incidental ingestion of oocytes from **cat feces** (felines are the definitive host).
- Consumption of **undercooked meat** from farm animals (eg, pigs, chickens, goats) that ingested oocytes and developed tissue infection.

Most cases in pregnant women arise due to the consumption of undercooked, contaminated meat. Although maternal infection is often

This neonate with retinal lesions (chorioretinitis), hydrocephalus, and a placenta infiltrated with crescent-shaped organisms likely has **congenital toxoplasmosis**, an infection caused by the **intracellular parasite** *Toxoplasma gondii*. Humans typically acquire the infection due to:

- Incidental ingestion of oocytes from **cat feces** (felines are the definitive host).
- Consumption of **undercooked meat** from farm animals (eg, pigs, chickens, goats) that ingested oocytes and developed tissue infection.

Most cases in pregnant women arise due to the consumption of undercooked, contaminated meat. Although maternal infection is often asymptomatic, the organism can spread across the placenta to the fetus, leading to congenital toxoplasmosis (eg, **chorioretinitis**, hydrocephalus, jaundice, hepatosplenomegaly). Therefore, pregnant women are advised to **avoid** raw, cured, and undercooked meat in order to reduce the risk of infection.

(Choice A) Rubella vaccination (measles, mumps, and rubella vaccine) can prevent congenital rubella infection, which is often characterized by growth restriction, hearing loss, cloudy cornea, and meningoencephalitis. Retinal lesions and hydrocephalus are uncommon, and rubella is a virus (not a crescent-shaped, intracellular parasite).

(Choice C) Pregnant women are advised to avoid unpasteurized milk products to prevent *Listeria monocytogenes* infection. Spread to the fetus can lead to fetal death or abscesses in multiple organs. *Listeria* is associated with chorioamnionitis but is marked by the presence of gram-positive rods that exhibit tumbling motility (not intracellular, crescent-shaped organisms).

(Choice D) Zika virus is a flavivirus transmitted by mosquitos. Infections in pregnant women can lead to transplacental spread of the virus to the fetal brain, causing microcephaly, ocular deficits, hearing loss, and growth restriction. Intracellular, crescent-shaped organisms would not be visualized.

(Choice E) Prophylactic penicillin administration during labor is used to prevent group B streptococcus (GBS) transmission to the fetus during delivery. Infection typically leads to early neonatal sepsis (eg, lethargy, hypoxia, temperature instability, hypotension) within the first 24 hours of delivery. GBS is a gram-positive diplococcus.

Educational objective:
Pregnant women should avoid raw or undercooked meat in order to prevent infection with *Toxoplasma gondii*, an intracellular parasite that can spread across the placenta to the fetus. Congenital toxoplasmosis is typically characterized by retinal lesions, hydrocephalus, jaundice, and hepatosplenomegaly.

Most cases in pregnant women arise due to the consumption of undercooked, contaminated meat. Although maternal infection is often asymptomatic, the organism can spread across the placenta to the fetus, leading to congenital toxoplasmosis (eg, **chorioretinitis**, hydrocephalus, jaundice, hepatosplenomegaly). Therefore, pregnant women are advised to **avoid** raw, cured, and undercooked meat in order to reduce the risk of infection.

(Choice A) Rubella vaccination (measles, mumps, and rubella vaccine) can prevent congenital rubella infection, which is often characterized by growth restriction, hearing loss, cloudy cornea, and meningoencephalitis. Retinal lesions and hydrocephalus are uncommon, and rubella is a virus (not a crescent-shaped, intracellular parasite).

(Choice C) Pregnant women are advised to avoid unpasteurized milk products to prevent *Listeria monocytogenes* infection. Spread to the fetus can lead to fetal death or abscesses in multiple organs. *Listeria* is associated with chorioamnionitis but is marked by the presence of gram-positive rods that exhibit tumbling motility (not intracellular, crescent-shaped organisms).

(Choice D) Zika virus is a flavivirus transmitted by mosquitos. Infections in pregnant women can lead to transplacental spread of the virus to the fetal brain, causing microcephaly, ocular deficits, hearing loss, and growth restriction. Intracellular, crescent-shaped organisms would not be visualized.

(Choice E) Prophylactic penicillin administration during labor is used to prevent group B streptococcus (GBS) transmission to the fetus during delivery. Infection typically leads to early neonatal sepsis (eg, lethargy, hypoxia, temperature instability, hypotension) within the first 24 hours of delivery. GBS is a gram-positive diplococcus.

Educational objective:
Pregnant women should avoid raw or undercooked meat in order to prevent infection with *Toxoplasma gondii*, an intracellular parasite that can spread across the placenta to the fetus. Congenital toxoplasmosis is typically characterized by retinal lesions, hydrocephalus, jaundice, and hepatosplenomegaly.

Microbiology	Infectious Diseases	Toxoplasmosis
Subject	System	Topic

Copyright © UWorld. All rights reserved.

A 34-year-old man came to the office due to white plaques on his buccal mucosa that he incidentally discovered while brushing his teeth. After appropriate workup, he was found to be HIV positive, with a CD4+ T lymphocyte count of 280/mm^3. He was referred to an infectious diseases specialist for follow-up but was noncompliant with appointments. The patient returns 3 years later due to several months of pain and itching in the perirectal area. He also has intermittent rectal bleeding and often sees bright red blood on the tissue after wiping. The patient did not seek medical care because he thought he had hemorrhoids. On examination, a single, hard mass with superficial ulceration measuring approximately 2x2 cm is noted in the anal canal. No hemorrhoids are present. There is no palpable regional lymphadenopathy. Which of the following pathogens is most likely responsible for this patient's current anal pathology?

- A. Adenovirus
- B. *Candida albicans*
- C. *Chlamydia trachomatis*
- D. Cytomegalovirus
- E. Epstein-Barr virus
- F. Herpes simplex virus type 2
- G. Human papillomavirus

Submit

A 34-year-old man came to the office due to white plaques on his buccal mucosa that he incidentally discovered while brushing his teeth. After appropriate workup, he was found to be HIV positive, with a CD4+ T lymphocyte count of 280/mm^3. He was referred to an infectious diseases specialist for follow-up but was noncompliant with appointments. The patient returns 3 years later due to several months of pain and itching in the perirectal area. He also has intermittent rectal bleeding and often sees bright red blood on the tissue after wiping. The patient did not seek medical care because he thought he had hemorrhoids. On examination, a single, hard mass with superficial ulceration measuring approximately 2x2 cm is noted in the anal canal. No hemorrhoids are present. There is no palpable regional lymphadenopathy. Which of the following pathogens is most likely responsible for this patient's current anal pathology?

- A. Adenovirus (0%)
- B. *Candida albicans* (5%)
- C. *Chlamydia trachomatis* (2%)
- D. Cytomegalovirus (7%)
- E. Epstein-Barr virus (4%)
- F. Herpes simplex virus type 2 (10%)
- ✓ G. Human papillomavirus (67%)

Omitted
Correct answer
G

67%
Answered correctly

01 sec
Time Spent

05/05/2020
Last Updated

Explanation

This patient with HIV likely has anal squamous cell carcinoma given the duration of pain, itching, and rectal bleeding in addition to the visible

This patient with HIV likely has **anal squamous cell carcinoma** given the duration of pain, itching, and rectal bleeding in addition to the visible **ulcerative mass** (anal cancers are ulcerative in >50% of cases). Anogenital squamous cell carcinomas and their precursors, squamous intraepithelial lesions, have been linked to **human papillomavirus** (HPV) infection. Intraepithelial neoplasias of the cervix, vulva, penis, and anus have a well-documented association with HPV types 16 and 18. A strong correlation between HPV and invasive carcinoma has been established for cervical cancer.

Immunodeficiency states (eg, AIDS) increase host susceptibility to HPV infection and more severe infection. **HIV**-positive men who have sex with men are at increased risk of developing anal squamous cell carcinoma (anal intercourse is hypothesized to be related), and HIV-positive women are more prone to developing cervical squamous cell carcinoma.

(Choice A) Adenoviruses can cause severe upper respiratory illnesses, pneumonia, and disseminated infection in immunosuppressed patients.

(Choices B and E) HIV-positive patients often experience reactivation of latent Epstein-Barr virus (EBV) infection. EBV replication in such patients is associated with certain lymphomas and with oral hairy leukoplakia, which typically manifests as white plaques on the lateral tongue margins (this patient's white buccal plaques on initial diagnosis were more likely thrush due to *Candida*).

(Choice C) *Chlamydia trachomatis* causes lymphogranuloma venereum (LGV), characterized by an ulcerative or vesicular lesion on the external genitalia followed by significant regional lymphadenopathy. Proctitis with tenesmus and bloody discharge can be seen with both LGV and anal carcinoma; however, LGV has a less indolent clinical course, and painful lymphadenopathy is a cardinal feature.

(Choice D) HIV-positive patients with CD4+ cell counts <100/mm^3 are at significantly increased risk of developing cytomegalovirus (CMV) infection, which most frequently causes retinitis in AIDS patients. CMV involvement of the gastrointestinal tract typically manifests as esophageal ulcers or colitis, not anal masses.

(Choice F) Although AIDS increases the prevalence of herpes simplex virus type 2 (HSV-2) infection and the frequency of symptomatic genital herpes recurrences, HSV-2 is not typically associated with anogenital carcinoma. A large, hard mass is not characteristic of herpetic lesions (classically painful vesicles or ulcers).

Educational objective:
Human papillomavirus (HPV) types 16 and 18 are strongly associated with anal and cervical squamous cell carcinoma. HIV infection increases the prevalence of HPV infection and the risk of anal carcinoma; this risk is further augmented in men who have sex with men.

(Choice A) Adenoviruses can cause severe upper respiratory illnesses, pneumonia, and disseminated infection in immunosuppressed patients.

(Choices B and E) HIV-positive patients often experience reactivation of latent Epstein-Barr virus (EBV) infection. EBV replication in such patients is associated with certain lymphomas and with oral hairy leukoplakia, which typically manifests as white plaques on the lateral tongue margins (this patient's white buccal plaques on initial diagnosis were more likely thrush due to *Candida*).

(Choice C) *Chlamydia trachomatis* causes lymphogranuloma venereum (LGV), characterized by an ulcerative or vesicular lesion on the external genitalia followed by significant regional lymphadenopathy. Proctitis with tenesmus and bloody discharge can be seen with both LGV and anal carcinoma; however, LGV has a less indolent clinical course, and painful lymphadenopathy is a cardinal feature.

(Choice D) HIV-positive patients with CD4+ cell counts <100/mm^3 are at significantly increased risk of developing cytomegalovirus (CMV) infection, which most frequently causes retinitis in AIDS patients. CMV involvement of the gastrointestinal tract typically manifests as esophageal ulcers or colitis, not anal masses.

(Choice F) Although AIDS increases the prevalence of herpes simplex virus type 2 (HSV-2) infection and the frequency of symptomatic genital herpes recurrences, HSV-2 is not typically associated with anogenital carcinoma. A large, hard mass is not characteristic of herpetic lesions (classically painful vesicles or ulcers).

Educational objective:
Human papillomavirus (HPV) types 16 and 18 are strongly associated with anal and cervical squamous cell carcinoma. HIV infection increases the prevalence of HPV infection and the risk of anal carcinoma; this risk is further augmented in men who have sex with men.

References

- Risk of human papillomavirus-associated cancers among persons with AIDS.
- Anal cancer: an overview.

Microbiology	Infectious Diseases	Anal cancer
Subject	System	Topic

Copyright © UWorld. All rights reserved.

A 42-year-old woman comes to the emergency department due to worsening jaw pain over the past week. She is unable to chew solid foods on the left side because of severe throbbing pain. The patient has had several "tooth infections" over the last year despite meticulous oral hygiene. Physical examination shows facial edema over the left mandible. Multiple teeth have decay and gingival recession, and gentle tapping of the left second molar elicits pain. This patient's current disease process is most likely to develop secondary to which of the following underlying conditions?

A. Acromegaly

B. Crohn disease

C. Riboflavin deficiency

D. Selective IgA deficiency

E. Sjögren syndrome

Submit

A 42-year-old woman comes to the emergency department due to worsening jaw pain over the past week. She is unable to chew solid foods on the left side because of severe throbbing pain. The patient has had several "tooth infections" over the last year despite meticulous oral hygiene. Physical examination shows facial edema over the left mandible. Multiple teeth have decay and gingival recession, and gentle tapping of the left second molar elicits pain. This patient's current disease process is most likely to develop secondary to which of the following underlying conditions?

- A. Acromegaly (1%)
- B. Crohn disease (1%)
- C. Riboflavin deficiency (6%)
- D. Selective IgA deficiency (12%)
- ✓ E. Sjögren syndrome (78%)

Omitted
Correct answer
E

78%
Answered correctly

01 sec
Time Spent

04/07/2020
Last Updated

Explanation

Sjögren syndrome	
Pathogenesis	• Immune-mediated destruction of the lacrimal & salivary glands • Can occur as primary disease or secondary with other autoimmune disorders (eg, SLE, RA)
	• Dry eyes (keratoconjunctivitis sicca)

Sjögren syndrome	
Pathogenesis	• Immune-mediated destruction of the lacrimal & salivary glands • Can occur as primary disease or secondary with other autoimmune disorders (eg, SLE, RA)
Clinical features	• Dry eyes (keratoconjunctivitis sicca) • Dry mouth (xerostomia), salivary hypertrophy • Dry skin (xerosis) • Raynaud phenomenon • Cutaneous vasculitis • Positive anti-Ro (SSA) &/or anti-La (SSB)
Complications	• Non-Hodgkin lymphoma • Corneal damage, dental caries

RA = rheumatoid arthritis; **SLE** = systemic lupus erythematosus; **SSA/SSB** = Sjögren syndrome (antibody) A/B.

Sjögren syndrome (SS) is an autoimmune disorder that is most common in middle-age women and is characterized by inflammation of exocrine glands (eg, salivary, lacrimal, vaginal). It can occur as an isolated disorder or in association with another autoimmune syndrome (eg, rheumatoid arthritis). Patients typically have severe dry mouth **(xerostomia)** due to **insufficient saliva** production.

Saliva has numerous antibacterial and antifungal proteins, along with organic and inorganic components which protect tooth enamel. Patients with SS have a higher rate of thrush, **dental caries**, and other complications of **odontogenic infections** (eg, osteomyelitis of the mandible) because of the loss of these protective factors in saliva.

Reduction in tear production from the lacrimal glands can cause corneal dryness and damage, and loss of vaginal lubrication in female patients is associated with dyspareunia (painful intercourse) and frequent infections (eg, candidal, bacterial). Biopsy of the salivary glands is diagnostic and shows a **lymphocytic infiltrate**, often with germinal centers.

(Choice A) Acromegaly is characterized by overproduction of growth hormone, typically due to a somatotroph pituitary adenoma. Cranial effects include enlarged facial features, prognathism, and increased spacing between the teeth.

Saliva has numerous antibacterial and antifungal proteins, along with organic and inorganic components which protect tooth enamel. Patients with SS have a higher rate of thrush, **dental caries**, and other complications of **odontogenic infections** (eg, osteomyelitis of the mandible) because of the loss of these protective factors in saliva.

Reduction in tear production from the lacrimal glands can cause corneal dryness and damage, and loss of vaginal lubrication in female patients is associated with dyspareunia (painful intercourse) and frequent infections (eg, candidal, bacterial). Biopsy of the salivary glands is diagnostic and shows a **lymphocytic infiltrate**, often with germinal centers.

(Choice A) Acromegaly is characterized by overproduction of growth hormone, typically due to a somatotroph pituitary adenoma. Cranial effects include enlarged facial features, prognathism, and increased spacing between the teeth.

(Choice B) Crohn disease can affect the entire gastrointestinal tract from the mouth to the anus. Aphthous ulcers are the most common oral manifestation of this disease.

(Choice C) Oral manifestations of riboflavin (vitamin B_2) deficiency include angular cheilosis, stomatitis, and glossitis.

(Choice D) Selective IgA deficiency is usually asymptomatic, although it is associated with an increased risk for giardiasis and recurrent sinopulmonary infections caused by encapsulated bacteria (eg, *Streptococcus pneumoniae*, *Haemophilus influenzae*).

Educational objective:
Sjögren syndrome is characterized by autoimmune inflammation of exocrine glands (eg, salivary, lacrimal, vaginal). Patients typically have severe dry mouth (xerostomia) due to reduced saliva production, which can lead to an increased rate of dental caries and other oral infections (eg, thrush) because of the loss of protective factors in saliva. Biopsy of the salivary glands shows a lymphocytic infiltrate, often with germinal centers.

References

- Epidemiology of Sjögren's syndrome—from an oral perspective.

Microbiology	Infectious Diseases	Odontogenic infections
Subject	System	Topic

Copyright © UWorld. All rights reserved.

Saliva has numerous antibacterial and antifungal proteins, along with organic and inorganic components which protect tooth enamel. Patients with

Exhibit Display

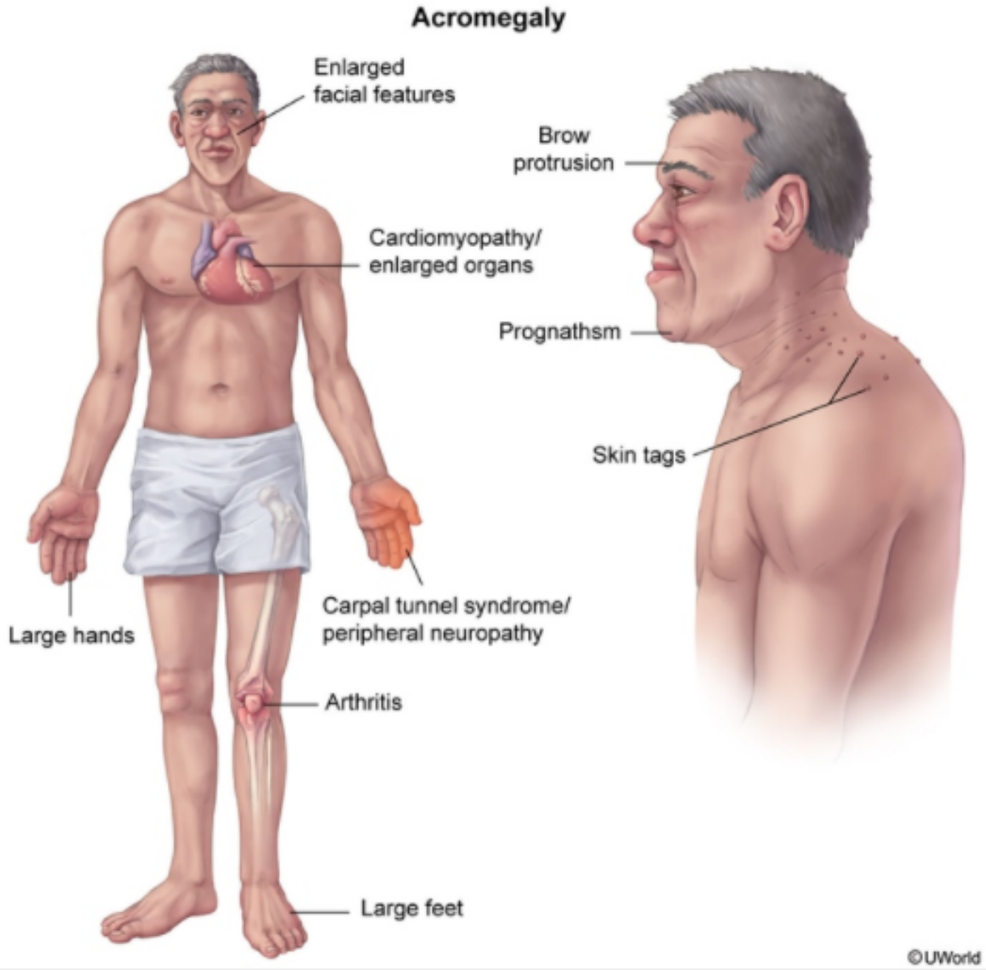

Zoom In | Zoom Out | Reset | Add To New Card | Existing Card

Saliva has numerous antibacterial and antifungal proteins, along with organic and inorganic components which protect tooth enamel. Patients with

Exhibit Display

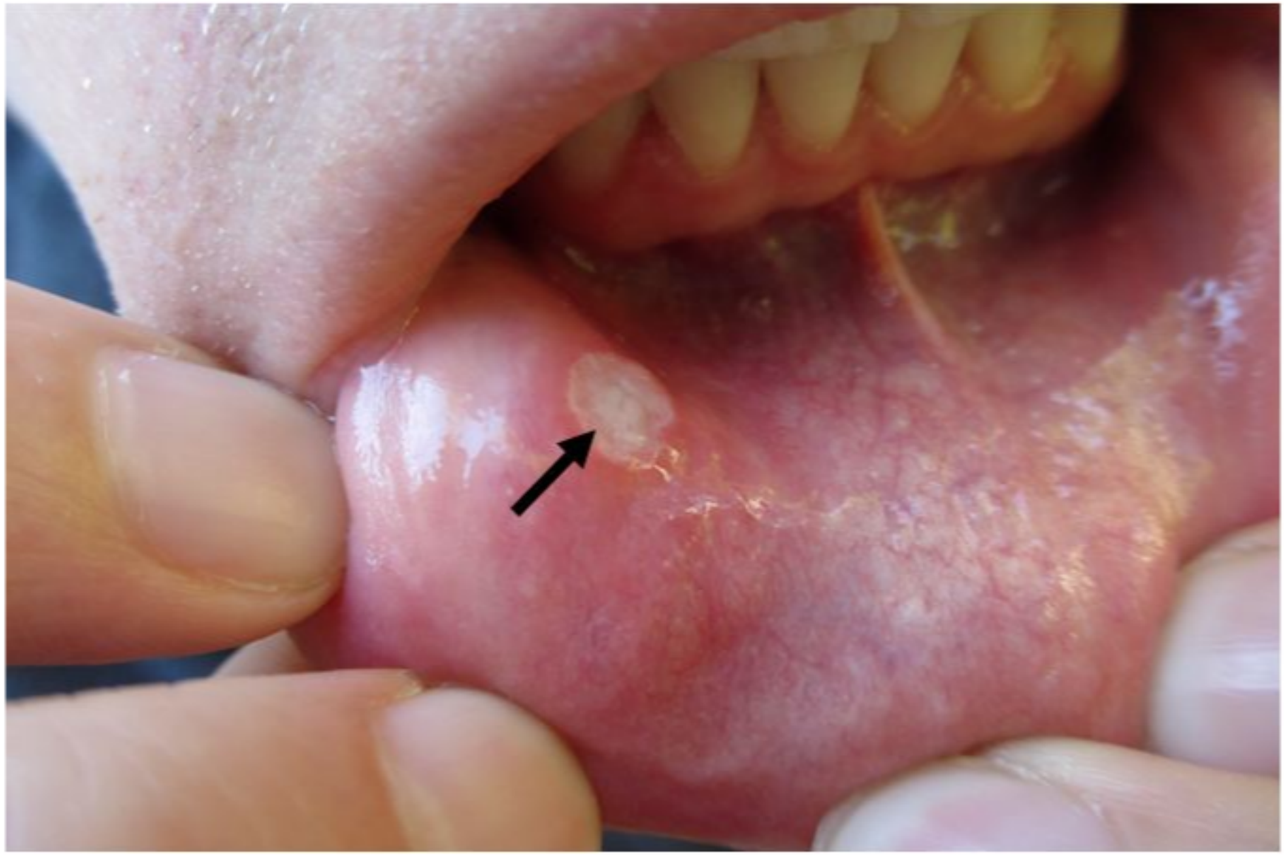

Zoom In | Zoom Out | Reset | Add To New Card | Existing Card

A microbiologist is studying the structure and function of bacterial cell walls. In an experiment, group A streptococci are treated with chemicals to solubilize the cell wall. Various cell wall–associated proteins are subsequently extracted. Electron microscopic evaluation of a specific protein shows structural homology with mammalian tropomyosin and myosin. This protein acts as a virulence factor for certain species of the organism. Which of the following is the most likely function of this bacterial cell wall–associated protein?

A. Excrete antibiotics

B. Protect from osmotic lysis

C. Provide mechanical cell support

D. Resist phagocytosis

E. Transport nutrients into the cell

Submit

A microbiologist is studying the structure and function of bacterial cell walls. In an experiment, group A streptococci are treated with chemicals to solubilize the cell wall. Various cell wall–associated proteins are subsequently extracted. Electron microscopic evaluation of a specific protein shows structural homology with mammalian tropomyosin and myosin. This protein acts as a virulence factor for certain species of the organism. Which of the following is the most likely function of this bacterial cell wall–associated protein?

- A. Excrete antibiotics (5%)
- B. Protect from osmotic lysis (7%)
- C. Provide mechanical cell support (31%)
- ✓ D. Resist phagocytosis (46%)
- E. Transport nutrients into the cell (8%)

Omitted
Correct answer
D

46%
Answered correctly

02 secs
Time Spent

03/07/2020
Last Updated

Explanation

Gram-positive organisms have cell walls composed primarily of a thick peptidoglycan layer and teichoic acid. However, additional cell wall components are often present that contribute to virulence, motility, or the ability to adhere to epithelial surfaces. For instance, the cell wall of **group A streptococcus** (also known as *Streptococcus pyogenes*) is studded with **M protein**, a virulence factor that **inhibits phagocytosis**, prevents complement binding, and aids in epithelial attachment.

M protein is an alpha-helical coiled-coil protein that shares epitopes and **structural homology** with other alpha-helical coiled-coil proteins such as **tropomyosin and myosin**. In some patients, the protective antibodies against M protein that develop in *S pyogenes* acute infection may cross-

Gram-positive organisms have cell walls composed primarily of a thick peptidoglycan layer and teichoic acid. However, additional cell wall components are often present that contribute to virulence, motility, or the ability to adhere to epithelial surfaces. For instance, the cell wall of **group A streptococcus** (also known as *Streptococcus pyogenes*) is studded with **M protein**, a virulence factor that **inhibits phagocytosis**, prevents complement binding, and aids in epithelial attachment.

M protein is an alpha-helical coiled-coil protein that shares epitopes and **structural homology** with other alpha-helical coiled-coil proteins such as **tropomyosin and myosin**. In some patients, the protective antibodies against M protein that develop in *S pyogenes* acute infection may cross-react with myosin epitopes in the heart and cause **rheumatic carditis**.

(Choice A) Efflux pumps are generally globular proteins with multiple domains. They reside in the bacterial cell membrane and excrete toxic substances from the interior of the cell. Bacteria can use efflux pumps to generate antibiotic resistance to drugs that operate in the interior of the cell, such as fluoroquinolones and aminoglycosides.

(Choices B and C) The bacterial cell wall of *S pyogenes* provides mechanical support and protects it from osmotic lysis. It is composed primarily of peptidoglycan, which forms a mesh-like, cross-linked polymer of peptides and sugars.

(Choice E) Porins in the cell membrane aid in the movement of nutrients into bacterial cells. They are composed of protein strands that group together to form a barrel (beta-barrel).

Educational objective:
The major virulence factor of *Streptococcus pyogenes* is M protein, an alpha-helical coiled-coil protein that shares structural homology with tropomyosin and myosin. It extends from the cell wall and prevents phagocytosis, inhibits complement binding, and mediates bacterial adherence. Antibodies against M protein form shortly after acute infection and may cross-react with epitopes on myosin, leading to rheumatic carditis.

References

- M protein and other surface proteins on streptococci.

Microbiology	Infectious Diseases	Pharyngitis
Subject	System	Topic

components are often present that contribute to virulence, motility, or the ability to adhere to epithelial surfaces. For instance, the cell wall of **group A streptococcus** (also known as *Streptococcus pyogenes*) is studded with **M protein**, a virulence factor that **inhibits phagocytosis**, prevents complement binding, and aids in epithelial attachment.

M protein is an alpha-helical coiled-coil protein that shares epitopes and **structural homology** with other alpha-helical coiled-coil proteins such as **tropomyosin and myosin**. In some patients, the protective antibodies against M protein that develop in *S pyogenes* acute infection may cross-react with myosin epitopes in the heart and cause **rheumatic carditis**.

(Choice A) Efflux pumps are generally globular proteins with multiple domains. They reside in the bacterial cell membrane and excrete toxic substances from the interior of the cell. Bacteria can use efflux pumps to generate antibiotic resistance to drugs that operate in the interior of the cell, such as fluoroquinolones and aminoglycosides.

(Choices B and C) The bacterial cell wall of *S pyogenes* provides mechanical support and protects it from osmotic lysis. It is composed primarily of peptidoglycan, which forms a mesh-like, cross-linked polymer of peptides and sugars.

(Choice E) Porins in the cell membrane aid in the movement of nutrients into bacterial cells. They are composed of protein strands that group together to form a barrel (beta-barrel).

Educational objective:
The major virulence factor of *Streptococcus pyogenes* is M protein, an alpha-helical coiled-coil protein that shares structural homology with tropomyosin and myosin. It extends from the cell wall and prevents phagocytosis, inhibits complement binding, and mediates bacterial adherence. Antibodies against M protein form shortly after acute infection and may cross-react with epitopes on myosin, leading to rheumatic carditis.

References

- M protein and other surface proteins on streptococci.

Microbiology	Infectious Diseases	Pharyngitis
Subject	System	Topic

Copyright © UWorld. All rights reserved.

components are often present that contribute to virulence, motility, or the ability to adhere to epithelial surfaces. For instance, the cell wall of

Exhibit Display

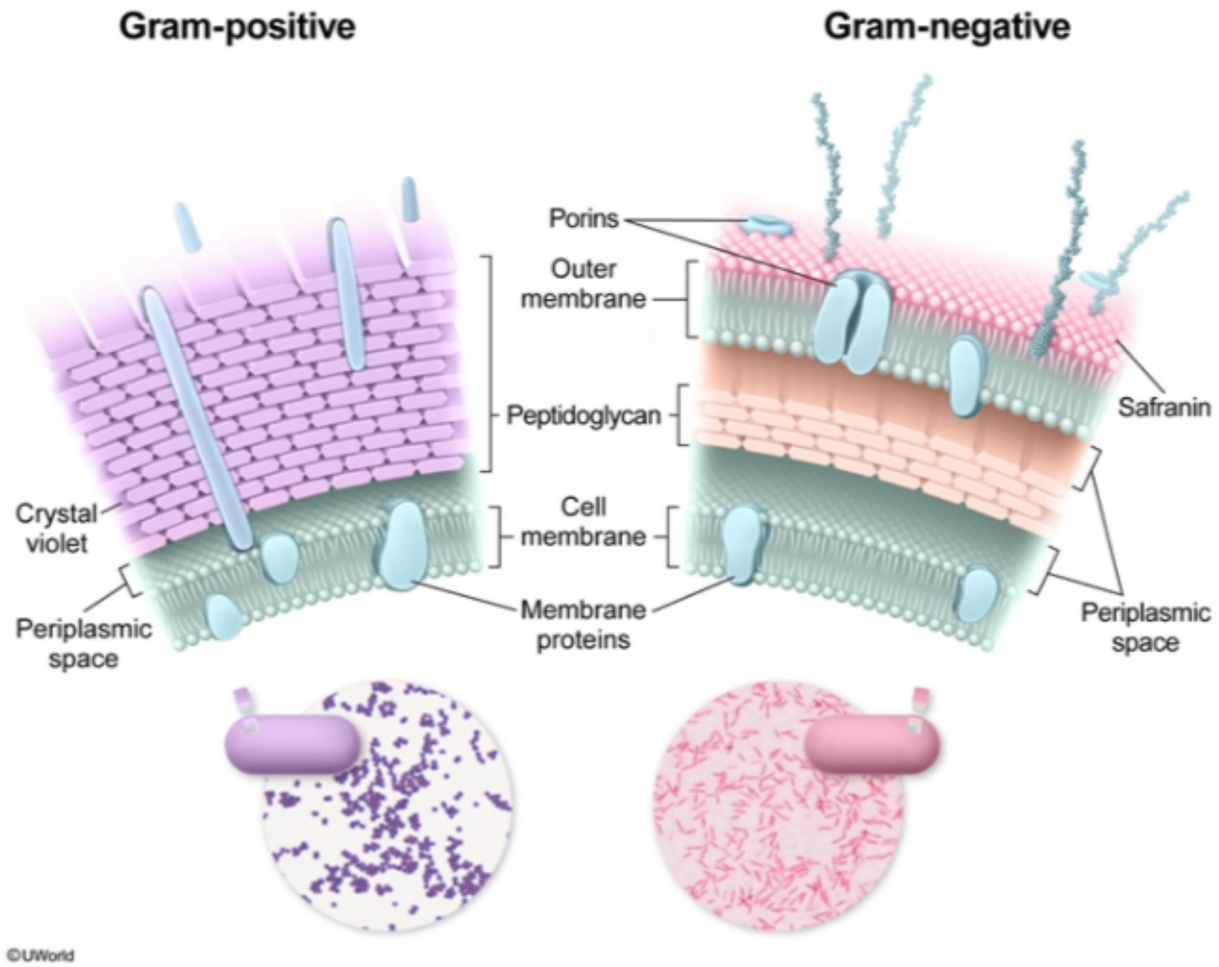

Zoom In | Zoom Out | Reset | Add To New Card | Existing Card

A 32-year-old man comes to the office due to diarrhea, flatulence, foul-smelling stools, and abdominal cramping. He recently returned home from a hiking trip. A smear of his stool sample is shown below:

Displayed with permission from Springer Healthcare Ltd. © Copyright 1997, 2004 by Current Medicine

Which of the following is the drug of choice for this condition?

- A. Ciprofloxacin
- B. Metronidazole
- C. Mebendazole
- D. Albendazole
- E. Loperamide

1
2
3
4
5
6
7
8
9
10
11
12
13
14
15
16
17
18
19
20
21
22
23
24
25
26
27
28
29
30
31

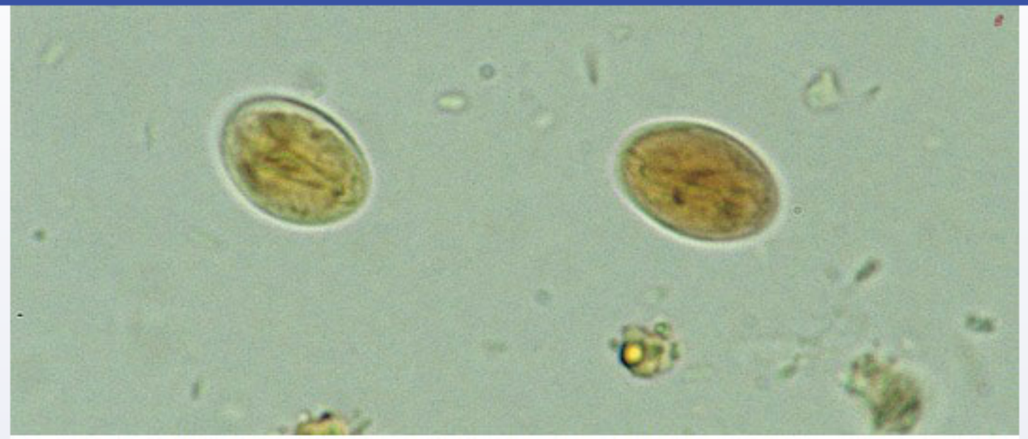

Displayed with permission from Springer Healthcare Ltd. © Copyright 1997, 2004 by Current Medicine

Which of the following is the drug of choice for this condition?

- A. Ciprofloxacin (2%)
- ✓ B. Metronidazole (79%)
- C. Mebendazole (9%)
- D. Albendazole (4%)
- E. Loperamide (1%)
- F. Clindamycin (1%)
- G. Erythromycin (0%)

Omitted
Correct answer

79%
Answered correctly

04 secs
Time Spent

02/03/2020
Last Updated

When examined for ova and parasites (stool smear with iodine staining), this patient's stool reveals ellipsoidal cysts with smooth, well-defined walls and 2+ nuclei, consistent with ***Giardia lamblia***. Other classic findings include pear-shaped, flagellated trophozoites. Giardia is the most common enteric parasite in the United States and Canada. When an individual drinks **contaminated water** from an endemic area without first boiling it, *Giardia* can colonize the duodenal and jejunal mucosal lining. Hikers and campers are particularly susceptible to infection.

Giardiasis causes chronic **diarrhea**, malabsorption, and **flatulence**. **Metronidazole** is an accepted treatment for this protozoan flagellate. This drug can also be used to treat *Helicobacter pylori* infections, amebiasis, and trichomoniasis.

(Choice A) Inflammatory traveler's diarrhea (marked by stool containing blood and mucus) can be treated with ciprofloxacin or another fluoroquinolone. Cysts would not be present.

(Choice C) Mebendazole is an anti-helminthic drug that acts on the microtubules of roundworms such as *Ancylostoma*, *Ascaris*, and *Enterobius*.

(Choice D) Albendazole is used to treat the tapeworm (cestode) *Echinococcus granulosus*. Echinococcus does not commonly cause diarrhea, but rather produces cysts in the liver and elsewhere.

(Choice E) Loperamide is an opiate antimotility drug that may be prescribed in some cases of traveler's diarrhea where there is no fever or blood in the stool.

(Choice F) Clindamycin has activity against anaerobes (eg, *Bacteroides fragilis*) and has some activity against some strains of staphylocci and streptococci.

(Choice G) Erythromycin can be used in lieu of fluoroquinolones to treat *Campylobacter jejuni*, as this organism has shown increasing worldwide resistance to fluoroquinolones.

Educational objective:
Giardia lamblia is the most common enteric parasite in the United States and Canada and is a common cause of diarrhea in campers/hikers. Iodine-stained stool smear classically shows pear-shaped, flagellated trophozoites or ellipsoidal cysts with smooth, well-defined walls and 2+ nuclei. Metronidazole is the treatment of choice.

Microbiology Infectious Diseases Giardia

common enteric parasite in the United States and Canada. When an individual drinks **contaminated water** from an endemic area without first boiling it, *Giardia* can colonize the duodenal and jejunal mucosal lining. Hikers and campers are particularly susceptible to infection.

Giardiasis causes chronic **diarrhea**, malabsorption, and **flatulence**. **Metronidazole** is an accepted treatment for this protozoan flagellate. This drug can also be used to treat *Helicobacter pylori* infections, amebiasis, and trichomoniasis.

(Choice A) Inflammatory traveler's diarrhea (marked by stool containing blood and mucus) can be treated with ciprofloxacin or another fluoroquinolone. Cysts would not be present.

(Choice C) Mebendazole is an anti-helminthic drug that acts on the microtubules of roundworms such as *Ancylostoma*, *Ascaris*, and *Enterobius*.

(Choice D) Albendazole is used to treat the tapeworm (cestode) *Echinococcus granulosus*. Echinococcus does not commonly cause diarrhea, but rather produces cysts in the liver and elsewhere.

(Choice E) Loperamide is an opiate antimotility drug that may be prescribed in some cases of traveler's diarrhea where there is no fever or blood in the stool.

(Choice F) Clindamycin has activity against anaerobes (eg, *Bacteroides fragilis*) and has some activity against some strains of staphylocci and streptococci.

(Choice G) Erythromycin can be used in lieu of fluoroquinolones to treat *Campylobacter jejuni*, as this organism has shown increasing worldwide resistance to fluoroquinolones.

Educational objective:
Giardia lamblia is the most common enteric parasite in the United States and Canada and is a common cause of diarrhea in campers/hikers. Iodine-stained stool smear classically shows pear-shaped, flagellated trophozoites or ellipsoidal cysts with smooth, well-defined walls and 2+ nuclei. Metronidazole is the treatment of choice.

Microbiology	Infectious Diseases	Giardia
Subject	System	Topic

Copyright © UWorld. All rights reserved.

An outbreak of diarrheal illness occurs in a community after a massive hurricane. The affected patients experience voluminous, watery diarrhea that quickly leads to severe dehydration. Stool examinations of these patients yield oxidase-positive, curved, highly motile, gram-negative rods. Epidemiologic study reveals the source as a contaminated water supply. Which of the following patient populations would be most susceptible to developing this illness?

A. Patients lacking a functional spleen

B. Patients taking proton pump inhibitors

C. Patients who recently took antibiotics

D. Patients with chronic liver disease

E. Patients with cystic fibrosis

Submit

An outbreak of diarrheal illness occurs in a community after a massive hurricane. The affected patients experience voluminous, watery diarrhea that quickly leads to severe dehydration. Stool examinations of these patients yield oxidase-positive, curved, highly motile, gram-negative rods. Epidemiologic study reveals the source as a contaminated water supply. Which of the following patient populations would be most susceptible to developing this illness?

- A. Patients lacking a functional spleen (8%)
- ✓ B. Patients taking proton pump inhibitors (65%)
- C. Patients who recently took antibiotics (9%)
- D. Patients with chronic liver disease (3%)
- E. Patients with cystic fibrosis (12%)

Omitted
Correct answer
B

65%
Answered correctly

02 secs
Time Spent

01/20/2020
Last Updated

Explanation

Vibrio cholerae is a comma-shaped, oxidase-positive, highly motile, gram-negative rod that is acquired after ingesting contaminated food or water. The infection is not invasive and does not disseminate outside of the gastrointestinal tract. However, the elaboration of the cholera enterotoxin leads to **severe, watery diarrhea** that can cause death from electrolyte imbalance and dehydration within 12 hours of symptom onset. Cholera is endemic in southern Asia and parts of Africa and Latin America, where seasonal outbreaks are common (peaks occur prior to and after rainy seasons). In the United States, the disease is rare and occurs mainly in patients who ingest contaminated seafood from the Gulf Coast.

Vibrio cholerae is a comma-shaped, oxidase-positive, highly motile, gram-negative rod that is acquired after ingesting contaminated food or water. The infection is not invasive and does not disseminate outside of the gastrointestinal tract. However, the elaboration of the cholera enterotoxin leads to **severe, watery diarrhea** that can cause death from electrolyte imbalance and dehydration within 12 hours of symptom onset. Cholera is endemic in southern Asia and parts of Africa and Latin America, where seasonal outbreaks are common (peaks occur prior to and after rainy seasons). In the United States, the disease is rare and occurs mainly in patients who ingest contaminated seafood from the Gulf Coast.

V cholerae must survive the acidic environment of the stomach to reach the small intestine and cause disease. Because the organism is very **acid-sensitive**, a high burden of *V cholerae* is generally required to cause clinical symptoms (>10^{10} organisms from contaminated water or >10^{6} organisms from contaminated food). However, those with inadequate gastric acid production (**achlorhydria**) can develop the disease with **much smaller infectious doses** as there is insufficient acid to kill the bacteria. Patients on long-term **proton pump inhibitor therapy** (eg, omeprazole) have pharmacologically induced achlorhydria; it can also be seen in those with gastritis.

(Choice A) Patients with splenectomy are at much higher risk of fulminant infection with encapsulated bacteria such as *Streptococcus pneumoniae*, *Neisseria meningitidis*, and *Haemophilus influenzae*. *V cholerae* is not encapsulated and not invasive; patients with splenectomy are unlikely to be at greater risk.

(Choice C) Recent antibiotic use is a strong risk factor for *Clostridium difficile* colitis, which typically manifests with watery diarrhea, abdominal pain, and low-grade fever. *C difficile* is a spore-forming, toxin-producing, gram-positive organism.

(Choice D) Patients with chronic liver disease are at increased risk for severe disease with *Vibrio vulnificus*, which can cause watery diarrhea. However, the ingestion of this pathogen usually leads to severe, rapid-onset sepsis in susceptible patients. In addition, *V vulnificus* is more likely to cause wound infections than gastroenteritis.

(Choice E) Patients with cystic fibrosis are at high risk for infections with *Pseudomonas aeruginosa*, an oxidase-positive, gram-negative rod. This pathogen is a common cause of pneumonia in this population; it does not cause gastroenteritis outbreaks.

Educational objective:
Vibrio cholerae must survive the acidic environment of the stomach to reach the small intestine and cause disease. Because the organism is easily destroyed by acid, a high burden of organisms must be ingested to cause infection. However, conditions that decrease gastric acidity (eg, antacid use) lower the minimum infectious dose of *V cholerae* by multiple orders of magnitude.

acid-sensitive, a high burden of *V cholerae* is generally required to cause clinical symptoms (>10^{10} organisms from contaminated water or >10^{6} organisms from contaminated food). However, those with inadequate gastric acid production (**achlorhydria**) can develop the disease with **much smaller infectious doses** as there is insufficient acid to kill the bacteria. Patients on long-term **proton pump inhibitor therapy** (eg, omeprazole) have pharmacologically induced achlorhydria; it can also be seen in those with gastritis.

(Choice A) Patients with splenectomy are at much higher risk of fulminant infection with encapsulated bacteria such as *Streptococcus pneumoniae*, *Neisseria meningitidis*, and *Haemophilus influenzae*. *V cholerae* is not encapsulated and not invasive; patients with splenectomy are unlikely to be at greater risk.

(Choice C) Recent antibiotic use is a strong risk factor for *Clostridium difficile* colitis, which typically manifests with watery diarrhea, abdominal pain, and low-grade fever. *C difficile* is a spore-forming, toxin-producing, gram-positive organism.

(Choice D) Patients with chronic liver disease are at increased risk for severe disease with *Vibrio vulnificus*, which can cause watery diarrhea. However, the ingestion of this pathogen usually leads to severe, rapid-onset sepsis in susceptible patients. In addition, *V vulnificus* is more likely to cause wound infections than gastroenteritis.

(Choice E) Patients with cystic fibrosis are at high risk for infections with *Pseudomonas aeruginosa*, an oxidase-positive, gram-negative rod. This pathogen is a common cause of pneumonia in this population; it does not cause gastroenteritis outbreaks.

Educational objective:
Vibrio cholerae must survive the acidic environment of the stomach to reach the small intestine and cause disease. Because the organism is easily destroyed by acid, a high burden of organisms must be ingested to cause infection. However, conditions that decrease gastric acidity (eg, antacid use) lower the minimum infectious dose of *V cholerae* by multiple orders of magnitude.

References

- Cholera.

Microbiology	Infectious Diseases	Cholera
Subject	System	Topic

Copyright © UWorld. All rights reserved.

A 38-year-old man comes to the office due to worsening fever, chills, malaise, cough, and shortness of breath. The patient has no prior medical conditions and does not use tobacco, alcohol, or illicit drugs. He has not traveled recently or been exposed to sick contacts. Temperature is 39.4 C (103 F). There is dullness to percussion and crackles over the right lung. Leukocyte count is elevated, and chest x-ray reveals a right lung infiltrate. The underlying immune response to this patient's infection largely involves T helper (Th1) cells, interferon-gamma, and interleukin-2. Which of the following is the most likely pathogen responsible for this patient's pneumonia?

A. *Haemophilus influenzae*

B. *Legionella pneumophila*

C. *Pseudomonas aeruginosa*

D. *Staphylococcus aureus*

E. *Streptococcus pneumoniae*

Submit

A 38-year-old man comes to the office due to worsening fever, chills, malaise, cough, and shortness of breath. The patient has no prior medical conditions and does not use tobacco, alcohol, or illicit drugs. He has not traveled recently or been exposed to sick contacts. Temperature is 39.4 C (103 F). There is dullness to percussion and crackles over the right lung. Leukocyte count is elevated, and chest x-ray reveals a right lung infiltrate. The underlying immune response to this patient's infection largely involves T helper (Th1) cells, interferon-gamma, and interleukin-2. Which of the following is the most likely pathogen responsible for this patient's pneumonia?

- A. *Haemophilus influenzae* (6%)
- ✓ B. *Legionella pneumophila* (35%)
- C. *Pseudomonas aeruginosa* (3%)
- D. *Staphylococcus aureus* (6%)
- E. *Streptococcus pneumoniae* (48%)

Omitted
Correct answer
B

35%
Answered correctly

02 secs
Time Spent

01/28/2020
Last Updated

Explanation

This patient has high fever, cough, leukocytosis, and a right lung infiltrate indicating **lobar pneumonia**. Lobar pneumonia is most commonly caused by extracellular bacterial pathogens such as *Haemophilus influenzae, Staphylococcus aureus*, and *Streptococcus pneumoniae* **(Choices A, D, and E)**. The immune response to extracellular organisms is primarily mediated by neutrophils early in infection and by the humoral antibody response (B lymphocytes, immunoglobulins, complement) as time goes on.

In this case, components of the **cell-mediated immune response** were primarily involved in controlling the infection, suggesting that the

This patient has high fever, cough, leukocytosis, and a right lung infiltrate indicating **lobar pneumonia**. Lobar pneumonia is most commonly caused by extracellular bacterial pathogens such as *Haemophilus influenzae, Staphylococcus aureus*, and *Streptococcus pneumoniae* **(Choices A, D, and E)**. The immune response to extracellular organisms is primarily mediated by neutrophils early in infection and by the humoral antibody response (B lymphocytes, immunoglobulins, complement) as time goes on.

In this case, components of the **cell-mediated immune response** were primarily involved in controlling the infection, suggesting that the pneumonia was most likely due to an **intracellular pathogen** such as ***Legionella pneumophila*** (a common cause of atypical community-acquired pneumonia). Intracellular pathogens are phagocytosed by macrophages but are initially resistant to destruction due to the presence of virulence factors that inhibit phagosome-lysosome fusion (eg, *Legionella*) or phagolysosome acidification (eg, *Mycobacteria tuberculosis*), or allow bacteria to escape from the phagolysosome (eg, *Listeria monocytogenes*).

Legionella and other intracellular pathogens that initially replicate within the phagosome eventually undergo some degree of digestion by lysosomes, leading to the display of bacterial antigens on major histocompatibility complex (MHC) class II molecules. This stimulates naïve CD4 T lymphocytes to differentiate into **T-helper subtype 1 (Th1) cells**. Th1 cells release **interferon-gamma**, which activates macrophages and allows them to form fully mature (acidified) phagolysosomes capable of efficiently killing the intracellular bacteria. Th1 cells also release **interleukin-2**, which activates and expands the population of naïve T cells, Th1 cells, and memory T cells.

(Choice C) *Pseudomonas aeruginosa* is a common cause of pneumonia in patients who are hospitalized in the intensive care unit or those with structural lung disease such as chronic obstructive pulmonary disease. It is an extracellular pathogen primarily combated by neutrophils and the humoral immune response.

Educational objective:
Intracellular bacterial organisms such as *Legionella pneumophila* are primarily countered by the cell-mediated immune response. Intracellular pathogens that replicate within phagosomes (eg, *Legionella*, *Mycobacterium tuberculosis*) trigger activation and differentiation of T-helper subtype 1 cells with subsequent macrophage activation via interferon-gamma.

Microbiology	Infectious Diseases	Legionella
Subject	System	Topic

Copyright © UWorld. All rights reserved.

This patient has high fever, cough, leukocytosis, and a right lung infiltrate indicating **lobar pneumonia**. Lobar pneumonia is most commonly

Exhibit Display

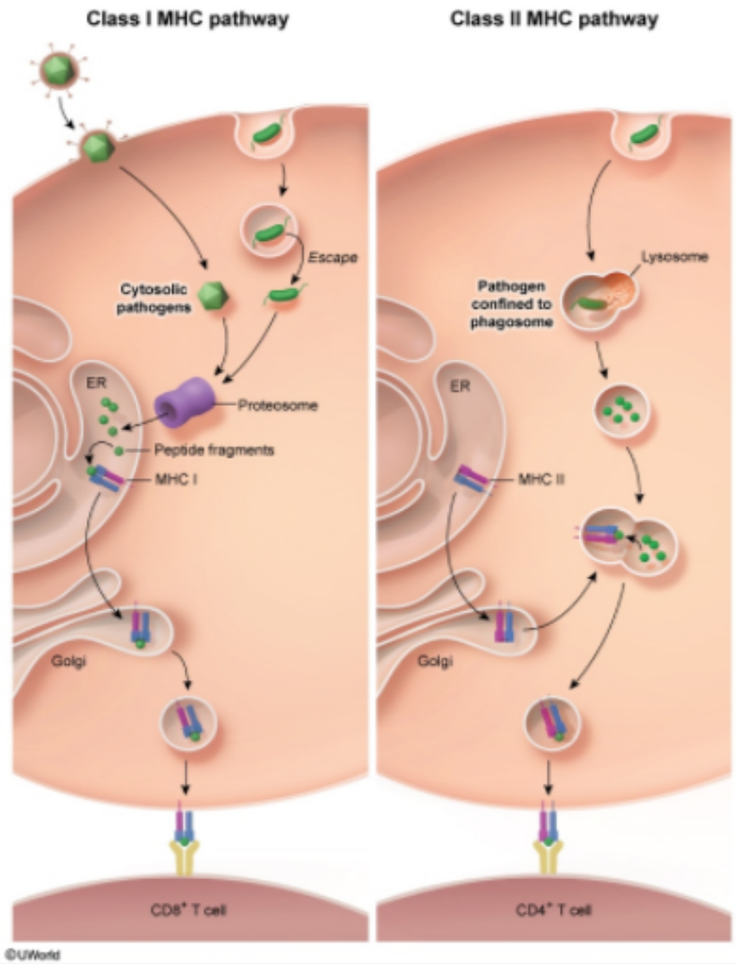

Zoom In Zoom Out Reset Add To Flash Card

A 25-year-old man with multiple injuries sustained in a motorcycle accident develops osteomyelitis while in the hospital. The organism is identified as methicillin-sensitive *Staphylococcus aureus*, and antibiotics are started. Which of the following is the most important measure to reduce the risk of transmission to other patients?

A. Contact precautions
B. Hand hygiene
C. Isolation precautions
D. Masks
E. Restricting visitors

Submit

A 25-year-old man with multiple injuries sustained in a motorcycle accident develops osteomyelitis while in the hospital. The organism is identified as methicillin-sensitive *Staphylococcus aureus*, and antibiotics are started. Which of the following is the most important measure to reduce the risk of transmission to other patients?

- A. Contact precautions (16%)
- ✓ B. Hand hygiene (69%)
- C. Isolation precautions (6%)
- D. Masks (6%)
- E. Restricting visitors (0%)

Omitted
Correct answer
B

69%
Answered correctly

02 secs
Time Spent

07/03/2020
Last Updated

Explanation

Hand hygiene by health care workers is the single most important measure to reduce the risk of transmission of microorganisms between patients. It includes handwashing with soap and water or using alcohol-based hand sanitizers that do not require water. Proper handwashing technique involves washing all surfaces of the hands and fingers with soap and water for at least 15 seconds, drying with a disposable towel, and using the towel to turn off the faucet. Alcohol-based hand sanitizer should cover all surfaces of the hands and fingers and be allowed to dry. The World Health Organization recommends handwashing before and after touching a patient, before aseptic procedures, and after contact with body fluids or patient surroundings.

(Choice A) Contact precautions involve wearing nonsterile gloves for all patient contact and gowns during substantial contact with infective

Explanation

Hand hygiene by health care workers is the single most important measure to reduce the risk of transmission of microorganisms between patients. It includes handwashing with soap and water or using alcohol-based hand sanitizers that do not require water. Proper handwashing technique involves washing all surfaces of the hands and fingers with soap and water for at least 15 seconds, drying with a disposable towel, and using the towel to turn off the faucet. Alcohol-based hand sanitizer should cover all surfaces of the hands and fingers and be allowed to dry. The World Health Organization recommends handwashing before and after touching a patient, before aseptic procedures, and after contact with body fluids or patient surroundings.

(Choice A) Contact precautions involve wearing nonsterile gloves for all patient contact and gowns during substantial contact with infective material. These precautions are indicated when caring for patients with specific multidrug-resistant bacteria (eg, methicillin-resistant *Staphylococcus aureus*, vancomycin-resistant enterococci) or with certain parasitic or viral pathogens. This patient's **methicillin-sensitive** *Staphylococcus aureus* infection does not require use of contact precautions.

(Choice C) Isolation precautions are indicated in the care of patients with infectious airborne diseases (eg, tuberculosis) and involve a private airborne infection isolation room with negative air pressure, closed doors, and the use of specialized particulate respirator masks.

(Choice D) Facemasks are used as a barrier for respiratory secretions and are not a substitute for hand-washing.

(Choice E) Restricting visitors is unnecessary, although all visitors should wash their hands before and after contact with the patient.

Educational objective:
Hand hygiene is the single most important measure to reduce the risk of transmission of hospital-acquired infections.

References

- Update on hand hygiene.

Microbiology	Infectious Diseases	Infection control
Subject	System	Topic

Copyright © UWorld. All rights reserved.

A 70-year-old man is hospitalized due to abrupt-onset, severe left thigh pain with no preceding trauma. Temperature is 38.9 C (102 F), blood pressure is 90/60 mm Hg, pulse is 120/min, and respirations are 24/min. Left thigh examination shows diffuse swelling with dusky skin discoloration and several bullae filled with hemorrhagic fluid. There is significant tenderness and crepitus on palpation. Gram staining of the bullae fluid reveals numerous gram-positive rods, and subsequent culture grows *Clostridium septicum*. Which of the following is the greatest risk factor for this patient's current condition?

- A. Colonic malignancy
- B. Hemochromatosis
- C. Indwelling vascular catheter
- D. Multiple myeloma
- E. Recent antibiotic use

Submit

A 70-year-old man is hospitalized due to abrupt-onset, severe left thigh pain with no preceding trauma. Temperature is 38.9 C (102 F), blood pressure is 90/60 mm Hg, pulse is 120/min, and respirations are 24/min. Left thigh examination shows diffuse swelling with dusky skin discoloration and several bullae filled with hemorrhagic fluid. There is significant tenderness and crepitus on palpation. Gram staining of the bullae fluid reveals numerous gram-positive rods, and subsequent culture grows *Clostridium septicum*. Which of the following is the greatest risk factor for this patient's current condition?

- ✓ A. Colonic malignancy (19%)
- B. Hemochromatosis (11%)
- C. Indwelling vascular catheter (32%)
- D. Multiple myeloma (10%)
- E. Recent antibiotic use (26%)

Omitted
Correct answer
A

19%
Answered correctly

02 secs
Time Spent

04/15/2020
Last Updated

Explanation

Clostridium septicum is a spore-forming, exotoxin-producing, gram-positive bacterium that is a normal commensal of the gastrointestinal tract in humans. Although the organism is largely nonpathogenic, breakdowns in the gastrointestinal mucosa can lead to invasion with subsequent **hematogenous dissemination** to healthy muscle tissue, resulting in **spontaneous gas gangrene** (nontraumatic). Manifestations include **rapid-onset muscle pain**, fever, **hemorrhagic bullae** with dusky surrounding skin, and tissue edema/**crepitus**. Urgent antibiotics and surgery are required, as the infection is often fatal even with early treatment.

Clostridium septicum is a spore-forming, exotoxin-producing, gram-positive bacterium that is a normal commensal of the gastrointestinal tract in humans. Although the organism is largely nonpathogenic, breakdowns in the gastrointestinal mucosa can lead to invasion with subsequent **hematogenous dissemination** to healthy muscle tissue, resulting in **spontaneous gas gangrene** (nontraumatic). Manifestations include **rapid-onset muscle pain**, fever, **hemorrhagic bullae** with dusky surrounding skin, and tissue edema/**crepitus**. Urgent antibiotics and surgery are required, as the infection is often fatal even with early treatment.

Most cases of spontaneous gas gangrene are triggered by an underlying **colonic malignancy**, which creates a portal of entry for the bacteria. Inflammatory bowel disease and immunosuppression are also risk factors. Unlike *C septicum* gas gangrene, *C perfringens* gas gangrene is usually associated with preceding trauma.

(Choice B) Patients with hemochromatosis are at increased risk for fulminant *Vibrio vulnificus* infections (the organism is dependent on free iron for growth). Although *V vulnificus* can cause rapid-onset sepsis and bullous skin lesions, it is a gram-negative bacterium. In addition, most infections occur due to shellfish consumption or wound contamination with seawater.

(Choice C) Indwelling vascular catheters increase the risk for candidemia, which can cause sepsis, abscesses, and pustular skin lesions on an erythematous base.

(Choice D) Multiple myeloma impairs lymphocyte function and reduces the ability of plasma cells to generate normal immunoglobulin, which increases risk of infection. Pneumonia due to *Streptococcus pneumoniae* and *Haemophilus influenzae* and urinary infections due to *Escherichia coli* are most common.

(Choice E) Recent antibiotic use increases the risk of *C difficile* infection, which usually presents with diarrhea, fever, and abdominal pain.

Educational objective:
Clostridium septicum is a spore-forming, exotoxin-producing, gram-positive organism that is the most common cause of spontaneous gas gangrene (eg, rapid-onset pain, hemorrhagic bullae, tissue crepitus). Underlying colonic malignancy is the greatest risk factor for infection.

Microbiology	Infectious Diseases	Clostridial myonecrosis
Subject	System	Topic

Copyright © UWorld. All rights reserved.

1
2
3
4
5
6
7
8
9
10
11
12
13
14
15
16
17
18
19
20
21
22
23
24
25
26
27
28
29
30
31

A previously healthy 23-year-old man comes to the office due to abrupt-onset high fever, chills, headache, and weakness that developed during a hiking and camping trip in New Mexico. His initial symptoms were quickly followed by intensely painful swellings in the groin. Physical examination shows tender and enlarged inguinal lymph nodes with overlying erythematous skin. Blood cultures and fluid aspirated from the lymph nodes grow gram-negative coccobacilli, which resemble a closed safety pin on special staining. Which of the following are the most likely source of this patient's infection?

A. Bats
B. Poultry
C. Rodents
D. Sheep
E. Swine

Submit

A previously healthy 23-year-old man comes to the office due to abrupt-onset high fever, chills, headache, and weakness that developed during a hiking and camping trip in New Mexico. His initial symptoms were quickly followed by intensely painful swellings in the groin. Physical examination shows tender and enlarged inguinal lymph nodes with overlying erythematous skin. Blood cultures and fluid aspirated from the lymph nodes grow gram-negative coccobacilli, which resemble a closed safety pin on special staining. Which of the following are the most likely source of this patient's infection?

A. Bats (6%)
B. Poultry (5%)
✓ C. Rodents (77%)
D. Sheep (7%)
E. Swine (3%)

Omitted
Correct answer
C

77%
Answered correctly

01 sec
Time Spent

02/14/2020
Last Updated

Explanation

This patient's acute febrile illness with tender, erythematous inguinal lymphadenopathy likely indicates **bubonic plague**, a zoonotic infection endemic to the Southwestern United States (eg, New Mexico). The causative pathogen is ***Yersinia pestis***, a gram-negative coccobacillus that exhibits **bipolar staining** (resembling a safety pin) on Giemsa or Wright stain. Although many small mammals can harbor the bacteria, **rodents** (eg, rats) are the primary environmental reservoir. Transmission to humans primarily occurs via rodent **flea bite**.

Following cutaneous injection, the organism travels to regional lymph nodes and triggers a significant inflammatory reaction. Manifestations

This patient's acute febrile illness with tender, erythematous inguinal lymphadenopathy likely indicates **bubonic plague**, a zoonotic infection endemic to the Southwestern United States (eg, New Mexico). The causative pathogen is ***Yersinia pestis***, a gram-negative coccobacillus that exhibits **bipolar staining** (resembling a safety pin) on Giemsa or Wright stain. Although many small mammals can harbor the bacteria, **rodents** (eg, rats) are the primary environmental reservoir. Transmission to humans primarily occurs via rodent **flea bite**.

Following cutaneous injection, the organism travels to regional lymph nodes and triggers a significant inflammatory reaction. Manifestations typically begin with acute fever, chills, weakness, and headache; **buboes** (painful, swollen, erythematous lymph nodes) develop shortly thereafter. Treatment with antibiotics (eg, aminoglycoside) is generally curative.

(Choice A) Bats can transmit rabies, which is characterized by nonspecific symptoms (eg, fever, myalgias, malaise) followed by hydrophobia, pharyngeal spasms, hyperactivity, coma, and death. Rabies is caused by a virus (*Lyssavirus*), not a gram-negative coccobacillus.

(Choice B) Non-typhoidal *Salmonella*, a motile gram-negative bacillus, is often transmitted via the ingestion of contaminated poultry. It causes febrile ("pea soup") diarrhea, not acute regional inflammatory lymphadenopathy.

(Choice D) Sheep hides can transmit anthrax, which is typically characterized by a necrotic skin ulcer with extensive surrounding edema and regional lymphadenopathy. *Bacillus anthracis*, the causative agent, is a gram-positive, spore-forming rod; infections are quite rare in the United States.

(Choice E) *Trichinella*, a roundworm transmitted by ingesting contaminated swine, is often associated with transient gastrointestinal symptoms followed by skeletal muscle pain, tenderness, swelling, and weakness.

Educational objective:
Bubonic plague is a zoonotic infection that causes febrile illness with regional inflammatory lymphadenopathy (buboes). The underlying pathogen is *Yersinia pestis*, a gram-negative coccobacillus that exhibits bipolar staining (resembling a closed safety pin). The major environmental reservoir is rodents, and transmission usually occurs via rodent flea bite.

References

- Plague.

Microbiology	Infectious Diseases	Plague
Subject	System	Topic

1
2
3
4
5
6
7
8
9
10
11
12
13
14
15
16
17
18
19
20
21
22
23
24
25
26
27
28
29
30
31

A 3-year-old girl is brought to the emergency department with abrupt-onset vomiting followed by frequent, large-volume, watery diarrhea for the last day. She has no prior medical conditions but has not received recommended vaccinations. Temperature is 37.8 C (100 F). Physical examination shows mild dehydration. The abdomen is soft and mildly tender to palpation throughout. Bowel sounds are increased. Polymerase chain reaction testing of the stool sample yields a virus with a segmented, double-stranded RNA genome. Which of the following pathologic findings is most likely to be present in this patient?

A. Blunting of the villi in the duodenum and proximal jejunum

B. Extensive colonic mucosal injury with yellow-white adherent layer

C. Flask-shaped ulcerations in the cecum and ascending colon

D. Foamy macrophages in the small intestinal lamina propria

E. Inflammatory infiltration and necrosis of the Peyer patches

Submit

A 3-year-old girl is brought to the emergency department with abrupt-onset vomiting followed by frequent, large-volume, watery diarrhea for the last day. She has no prior medical conditions but has not received recommended vaccinations. Temperature is 37.8 C (100 F). Physical examination shows mild dehydration. The abdomen is soft and mildly tender to palpation throughout. Bowel sounds are increased. Polymerase chain reaction testing of the stool sample yields a virus with a segmented, double-stranded RNA genome. Which of the following pathologic findings is most likely to be present in this patient?

- ✓ A. Blunting of the villi in the duodenum and proximal jejunum (44%)
- B. Extensive colonic mucosal injury with yellow-white adherent layer (8%)
- C. Flask-shaped ulcerations in the cecum and ascending colon (5%)
- D. Foamy macrophages in the small intestinal lamina propria (10%)
- E. Inflammatory infiltration and necrosis of the Peyer patches (31%)

Omitted
Correct answer
A

44%
Answered correctly

03 secs
Time Spent

02/10/2020
Last Updated

Explanation

Rotavirus is a segmented, nonenveloped, double-stranded RNA virus that is primarily transmitted via the fecal-oral route. It is a major cause of infectious diarrhea in children worldwide and typically presents in those **age <5** with acute, self-limited fever and watery diarrhea that may lead to dehydration and electrolyte abnormalities. Rotavirus vaccination is protective and has resulted in a dramatic reduction in disease incidence.

Rotavirus invades the villous epithelium of the **duodenum and proximal jejunum**. Infection causes diarrhea via multiple mechanisms including **villous blunting** (loss of absorptive capacity), proliferation of secretory crypt cells (secretory diarrhea), and reduced brush border enzymes

Rotavirus is a segmented, nonenveloped, double-stranded RNA virus that is primarily transmitted via the fecal-oral route. It is a major cause of infectious diarrhea in children worldwide and typically presents in those **age <5** with acute, self-limited fever and watery diarrhea that may lead to dehydration and electrolyte abnormalities. Rotavirus vaccination is protective and has resulted in a dramatic reduction in disease incidence.

Rotavirus invades the villous epithelium of the **duodenum and proximal jejunum**. Infection causes diarrhea via multiple mechanisms including **villous blunting** (loss of absorptive capacity), proliferation of secretory crypt cells (secretory diarrhea), and reduced brush border enzymes (accumulation of unmetabolized disaccharides in the small intestine lumen). Rotavirus is noninflammatory; therefore, fecal leukocytes and erythrocytes are not typically seen. Repeat infections are often less severe than initial infection due to the generation of protective secretory IgA against rotaviral antigens.

(Choice B) *Clostridium difficile* infection causes exotoxin-mediated damage to the large intestine mucosa, leading to the development of yellow-white pseudomembranes. Cases are most common after recent antibiotic therapy and usually present with watery diarrhea, fever, and abdominal pain. *C difficile* is a spore-forming, gram-positive bacterium.

(Choice C) *Entamoeba histolytica* is a common cause of dysentery and extraintestinal disease (eg, liver abscess) in the developing world. Gastrointestinal infection usually results in bloody stools and fever; colonic visualization classically reveals flask-shaped ulcers (ie, with overhanging edges) in the cecum and ascending colon.

(Choice D) Whipple disease is caused by the gram-positive bacillus *Tropheryma whipplei*. Histopathology of the small intestine classically shows foamy macrophages in the lamina propria. Manifestations usually include arthralgias and chronic diarrhea with malabsorption and weight loss.

(Choice E) Typhoid strains of *Salmonella* pass through enterocytes and invade macrophages in the intestinal submucosa and Peyer patches. Inflammation and necrosis of Peyer patches can lead to life-threatening gastrointestinal bleeding and perforation.

Educational objective:
Rotavirus is a common cause of self-limited childhood diarrhea in unvaccinated individuals. It infects villous enterocytes in the duodenum and proximal jejunum and results in villous blunting, proliferation of secretory crypt cells, and a loss of brush border enzymes; this results in watery diarrhea without fecal leukocytes.

Microbiology	Infectious Diseases	Acute diarrhea
Subject	System	Topic

dehydration and electrolyte abnormalities. Rotavirus vaccination is protective and has resulted in a dramatic reduction in disease incidence.

Rotavirus invades the villous epithelium of the **duodenum and proximal jejunum**. Infection causes diarrhea via multiple mechanisms including **villous blunting** (loss of absorptive capacity), proliferation of secretory crypt cells (secretory diarrhea), and reduced brush border enzymes (accumulation of unmetabolized disaccharides in the small intestine lumen). Rotavirus is noninflammatory; therefore, fecal leukocytes and erythrocytes are not typically seen. Repeat infections are often less severe than initial infection due to the generation of protective secretory IgA against rotaviral antigens.

(Choice B) *Clostridium difficile* infection causes exotoxin-mediated damage to the large intestine mucosa, leading to the development of yellow-white pseudomembranes. Cases are most common after recent antibiotic therapy and usually present with watery diarrhea, fever, and abdominal pain. *C difficile* is a spore-forming, gram-positive bacterium.

(Choice C) *Entamoeba histolytica* is a common cause of dysentery and extraintestinal disease (eg, liver abscess) in the developing world. Gastrointestinal infection usually results in bloody stools and fever; colonic visualization classically reveals flask-shaped ulcers (ie, with overhanging edges) in the cecum and ascending colon.

(Choice D) Whipple disease is caused by the gram-positive bacillus *Tropheryma whipplei*. Histopathology of the small intestine classically shows foamy macrophages in the lamina propria. Manifestations usually include arthralgias and chronic diarrhea with malabsorption and weight loss.

(Choice E) Typhoid strains of *Salmonella* pass through enterocytes and invade macrophages in the intestinal submucosa and Peyer patches. Inflammation and necrosis of Peyer patches can lead to life-threatening gastrointestinal bleeding and perforation.

Educational objective:
Rotavirus is a common cause of self-limited childhood diarrhea in unvaccinated individuals. It infects villous enterocytes in the duodenum and proximal jejunum and results in villous blunting, proliferation of secretory crypt cells, and a loss of brush border enzymes; this results in watery diarrhea without fecal leukocytes.

Microbiology	Infectious Diseases	Acute diarrhea
Subject	System	Topic

Copyright © UWorld. All rights reserved.

dehydration and electrolyte abnormalities. Rotavirus vaccination is protective and has resulted in a dramatic reduction in disease incidence.

Exhibit Display

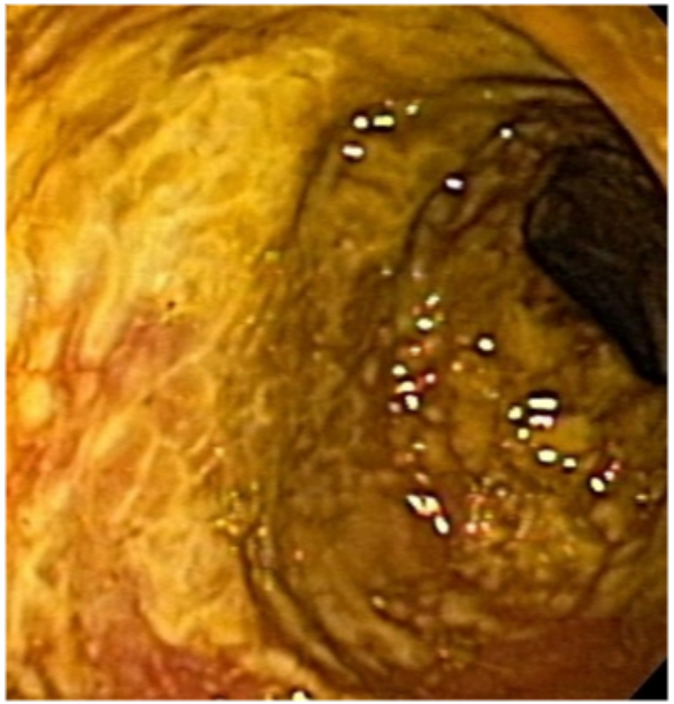

Zoom In | Zoom Out | Reset | Add To New Card | Existing Card

1 2 3 4 5 6 7 8 9 10 11 12 13 14 15 16 17 18 19 20 21 22 23 24 25 26 27 28 29 30 31

dehydration and electrolyte abnormalities. Rotavirus vaccination is protective and has resulted in a dramatic reduction in disease incidence.

Exhibit Display

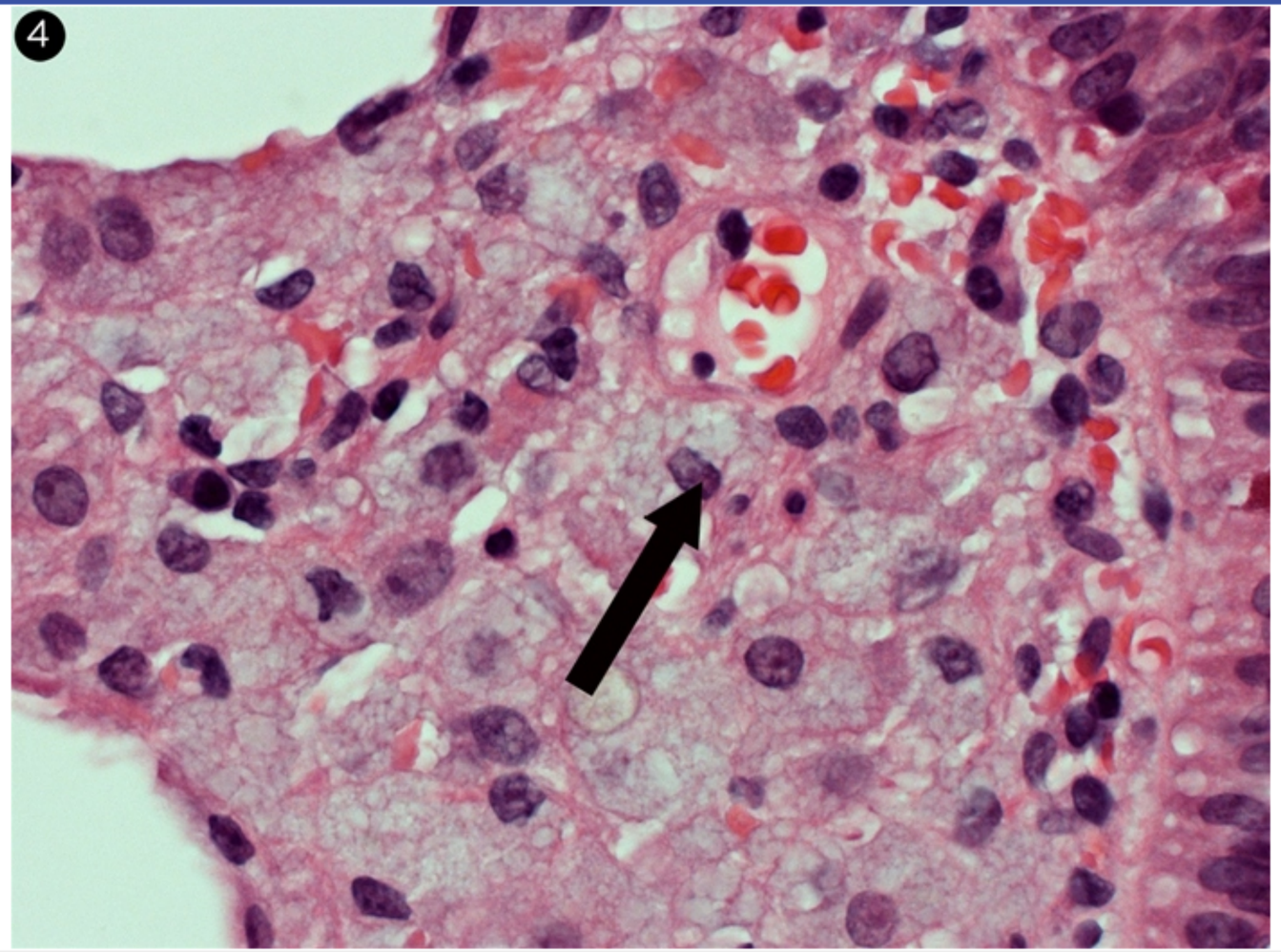

Zoom In Zoom Out Reset Add To New Card | Existing Card

1
2
3
4
5
6
7
8
9
10
11
12
13
14
15
16
17
18
19
20
21
22
23
24
25
26
27
28
29
30
31

A 21-year-old man comes to the office due to several days of intense pruritus of the inguinal-genital area. He has had no fever, dysuria, or skin rash. He is not using any new soaps, detergents, or lotions. The patient has had 3 sexual partners in the past year. He was treated for chlamydial urethritis 6 months ago and since then has been using condoms consistently. Vital signs are within normal limits. Genitourinary examination shows no urethral discharge, penile lesions, or inguinal lymphadenopathy. There are skin excoriation marks in the pubic area and other findings as shown in the exhibit. Which of the following is the most appropriate pharmacotherapy for this patient's condition?

A. Oral acyclovir
B. Oral doxycycline
C. Oral fluconazole
D. Topical imiquimod
E. Topical permethrin
F. Topical triamcinolone

Submit

1
2
3
4
5
6
7
8
9
10
11
12
13
14
15
16
17
18
19
20
21
22
23
24
25
26
27
28
29
30
31

Exhibit Display

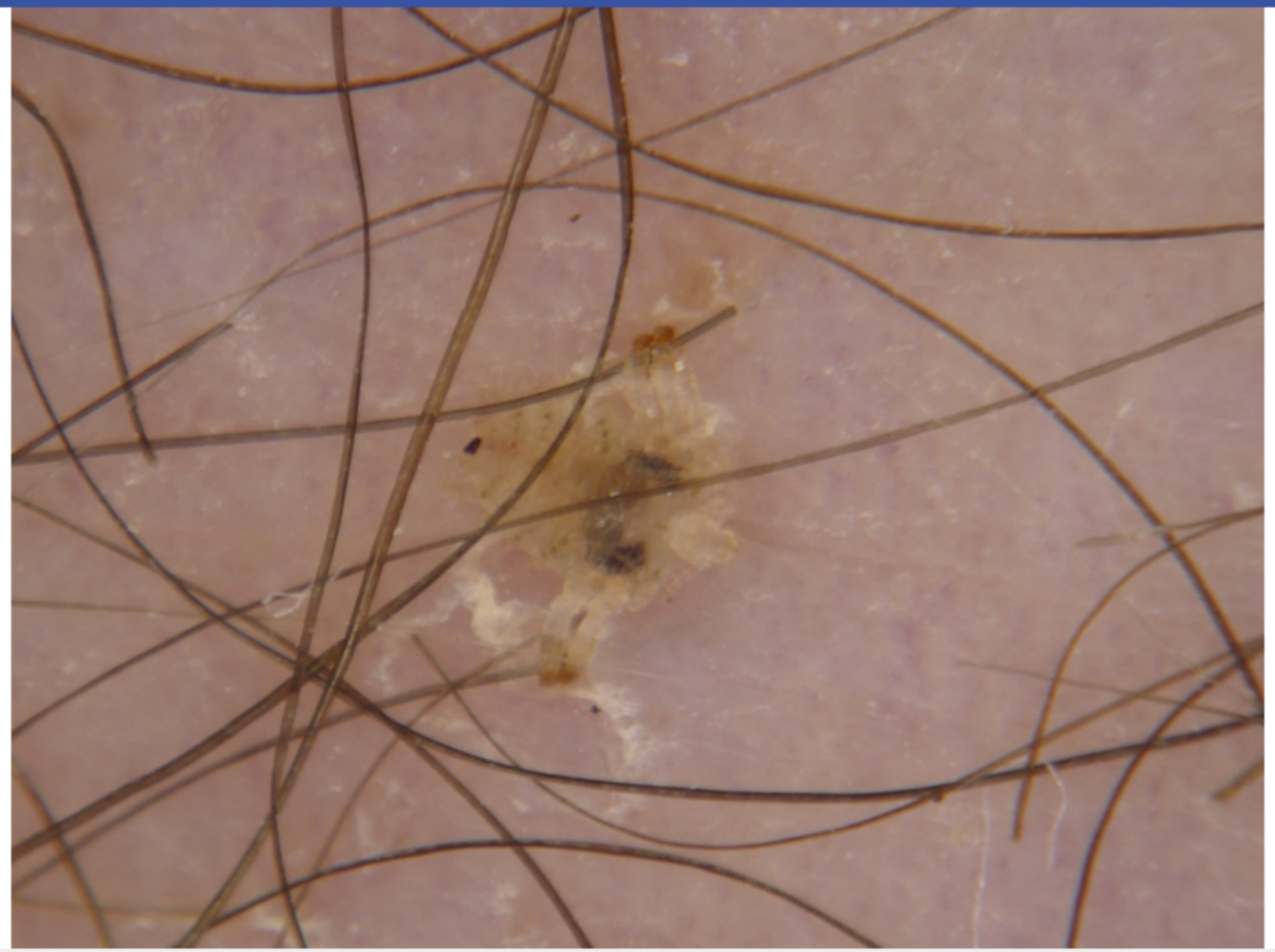

Zoom In | Zoom Out | Reset | Add To New Card | Existing Card

A 21-year-old man comes to the office due to several days of intense pruritus of the inguinal-genital area. He has had no fever, dysuria, or skin rash. He is not using any new soaps, detergents, or lotions. The patient has had 3 sexual partners in the past year. He was treated for chlamydial urethritis 6 months ago and since then has been using condoms consistently. Vital signs are within normal limits. Genitourinary examination shows no urethral discharge, penile lesions, or inguinal lymphadenopathy. There are skin excoriation marks in the pubic area and other findings as shown in the exhibit. Which of the following is the most appropriate pharmacotherapy for this patient's condition?

A. Oral acyclovir (3%)
B. Oral doxycycline (7%)
C. Oral fluconazole (10%)
D. Topical imiquimod (7%)
✓ E. Topical permethrin (63%)
F. Topical triamcinolone (6%)

Omitted
Correct answer
E

63%
Answered correctly

10 secs
Time Spent

04/23/2020
Last Updated

Explanation

Phthirus pubis, the human pubic louse, is a translucent parasite approximately 1 mm long with crab-like claws that allow it to grip pubic hair. Transmission usually occurs during **sexual contact** whereby an infected individual transmits the louse to an uninfected individual by skin-to-skin contact. Therefore, condoms are unable to prevent transmission (it is not transmitted by fluids). Teenagers and **young adults** are affected most commonly due to higher numbers of sexual partners.

1
2
3
4
5
6
7
8
9
10
11
12
13
14
15
16
17
18
19
20
21
22
23
24
25
26
27
28
29
30
31

Phthirus pubis, the human pubic louse, is a translucent parasite approximately 1 mm long with crab-like claws that allow it to grip pubic hair. Transmission usually occurs during **sexual contact** whereby an infected individual transmits the louse to an uninfected individual by skin-to-skin contact. Therefore, condoms are unable to prevent transmission (it is not transmitted by fluids). Teenagers and **young adults** are affected most commonly due to higher numbers of sexual partners.

Manifestations typically include **intense pruritus** in the pubic area with excoriations due to scratching. Other hairy areas such as the axillae may be affected, but the scalp is typically spared. Visualization of the louse or nits (oval, white, louse eggs on the hair shaft) confirms the diagnosis. First-line treatment includes a **topical permethrin cream** to the affected area. Permethrin blocks parasite sodium ion conduction in nerve cell membrane channels and results in louse paralysis and death.

(Choice A) Oral acyclovir is used for genital herpes simplex virus infection, which usually causes painful vesicular genital lesions on an erythematous base.

(Choice B) Oral doxycycline is first-line treatment for hidradenitis suppurativa, a chronic follicular occlusive disease that manifests in the intertriginous skin areas (eg, groin, axilla, inframammary). Manifestations usually include recurrent inflammatory nodules and abscesses with pain and malodorous discharge.

(Choice C) Oral fluconazole can be used to treat mucocutaneous *Candida* infections. *Candida* balanitis can cause severe pruritus but would be associated with white patches on an erythematous base.

(Choice D) Topical imiquimod increases the immune-response to anogenital warts due to human papilloma virus infection. It stimulates interferon-alpha, tumor necrosis factor, and interleukin-1/6/8. Anogenital warts can have many presentations (eg, flat, dome-shaped, filiform, pedunculated, verrucous) and may occasionally be pruritic.

(Choice F) Topical corticosteroids can be used to treat inflammatory cutaneous conditions such as psoriasis and contact dermatitis. Although these conditions can cause erythema and pruritus, they would not be associated with a translucent louse on examination.

Educational objective:
Phthirus pubis is the human pubic louse. It is transmitted sexually via skin-to-skin contact and causes intense pruritus. Louse and nits can often be visualized on examination, which is diagnostic. Treatment with topical permethrin is generally curative.

1
2
3
4
5
6
7
8
9
10
11
12
13
14
15
16
17
18
19
20
21
22
23
24
25
26
27
28
29
30
31

Exhibit Display

Zoom In
Zoom Out
Reset
Add To New Card | Existing Card

1
2
3
4
5
6
7
8
9
10
11
12
13
14
15
16
17
18
19
20
21
22
23
24
25
26
27
28
29
30
31

Exhibit Display

Zoom In | Zoom Out | Reset | Add To New Card | Existing Card

be affected, but the scalp is typically spared. Visualization of the louse or nits (oval, white, louse eggs on the hair shaft) confirms the diagnosis. First-line treatment includes a **topical permethrin cream** to the affected area. Permethrin blocks parasite sodium ion conduction in nerve cell membrane channels and results in louse paralysis and death.

(Choice A) Oral acyclovir is used for genital herpes simplex virus infection, which usually causes painful vesicular genital lesions on an erythematous base.

(Choice B) Oral doxycycline is first-line treatment for hidradenitis suppurativa, a chronic follicular occlusive disease that manifests in the intertriginous skin areas (eg, groin, axilla, inframammary). Manifestations usually include recurrent inflammatory nodules and abscesses with pain and malodorous discharge.

(Choice C) Oral fluconazole can be used to treat mucocutaneous *Candida* infections. *Candida* balanitis can cause severe pruritus but would be associated with white patches on an erythematous base.

(Choice D) Topical imiquimod increases the immune-response to anogenital warts due to human papilloma virus infection. It stimulates interferon-alpha, tumor necrosis factor, and interleukin-1/6/8. Anogenital warts can have many presentations (eg, flat, dome-shaped, filiform, pedunculated, verrucous) and may occasionally be pruritic.

(Choice F) Topical corticosteroids can be used to treat inflammatory cutaneous conditions such as psoriasis and contact dermatitis. Although these conditions can cause erythema and pruritus, they would not be associated with a translucent louse on examination.

Educational objective:
Phthirus pubis is the human pubic louse. It is transmitted sexually via skin-to-skin contact and causes intense pruritus. Louse and nits can often be visualized on examination, which is diagnostic. Treatment with topical permethrin is generally curative.

References

- Scabies and pediculosis pubis: an update of treatment regimens and general review.

Microbiology	Infectious Diseases	Lice infestation
Subject	System	Topic

Copyright © UWorld. All rights reserved.

1
2
3
4
5
6
7
8
9
10
11
12
13
14
15
16
17
18
19
20
21
22
23
24
25
26
27
28
29
30
31

A diarrheal outbreak is reported at a private school in Columbus, Ohio. Six healthy children age 10-11 and two teachers developed acute vomiting and diarrhea within a 2-day period. They describe the diarrhea as watery and without blood or mucus. Three of those affected are febrile during their illness. None of the patients have traveled abroad recently, and all are up to date with their immunizations. Stool test results are pending. Which of the following pathogens is the most likely cause of the illness?

A. Adenovirus
B. *Campylobacter jejuni*
C. *Clostridium difficile*
D. Enterotoxigenic *Escherichia coli*
E. Norovirus
F. Rotavirus
G. *Salmonella typhi*

Submit

A diarrheal outbreak is reported at a private school in Columbus, Ohio. Six healthy children age 10-11 and two teachers developed acute vomiting and diarrhea within a 2-day period. They describe the diarrhea as watery and without blood or mucus. Three of those affected are febrile during their illness. None of the patients have traveled abroad recently, and all are up to date with their immunizations. Stool test results are pending. Which of the following pathogens is the most likely cause of the illness?

- A. Adenovirus (5%)
- B. *Campylobacter jejuni* (2%)
- C. *Clostridium difficile* (1%)
- D. Enterotoxigenic *Escherichia coli* (7%)
- ✓ E. Norovirus (53%)
- F. Rotavirus (27%)
- G. *Salmonella typhi* (2%)

Omitted
Correct answer
E

53%
Answered correctly

03 secs
Time Spent

04/28/2020
Last Updated

Explanation

Norovirus	

Norovirus	
Epidemiology	• Single-stranded RNA genome • Most common cause of viral gastroenteritis in developed countries
Clinical features	• Acute onset; resolves in 2-3 days • Vomiting &/or diarrhea (no blood or mucus)

©UWorld

Norovirus is the most common cause of **viral gastroenteritis**. Symptoms include diarrhea, **vomiting**, fever, malaise, and headache. The **diarrhea** is typically **watery without blood or mucus** due to lack of small bowel inflammation.

Norovirus (part of the Calicivirus family) possesses a linear, nonenveloped, single-stranded RNA genome. It is resistant to inactivation by acid, bile, and pancreatic enzymes. As a result, norovirus is easily transmitted via **fecal-oral spread** (eg, foodborne, person-to-person via contaminated bodily fluids) and results in **outbreaks** in crowded settings (eg, schools, hospitals, cruise ships, nursing homes). The incubation period is 1-2 days; symptoms develop acutely and self-resolve within days. The diagnosis is typically based solely on clinical presentation, but polymerase chain reaction testing may be performed to confirm an outbreak.

(Choice A) Adenoviral gastroenteritis typically presents with fever and watery diarrhea. Outbreaks can occur, but these are far less common than with norovirus. Adenovirus more commonly causes pharyngoconjunctivitis and coryza (runny nose, nasal congestion).

(Choice B) Vomiting, high fever, and bloody diarrhea are typical of *Campylobacter jejuni* enteritis. Transmission occurs via oral contact with contaminated food (eg, poultry) or drinks. Outbreaks are not as common as those of viral etiology.

(Choice C) *Clostridium difficile* infection can result in asymptomatic carriers, pseudomembranous colitis, or fulminant colitis. Patients have watery diarrhea with or without blood, abdominal pain, fever, and leukocytosis. Prior antibiotic exposure (eg, penicillin, fluoroquinolones, clindamycin) is the most significant risk factor.

©UWorld

Norovirus is the most common cause of **viral gastroenteritis**. Symptoms include diarrhea, **vomiting**, fever, malaise, and headache. The **diarrhea** is typically **watery without blood or mucus** due to lack of small bowel inflammation.

Norovirus (part of the Calicivirus family) possesses a linear, nonenveloped, single-stranded RNA genome. It is resistant to inactivation by acid, bile, and pancreatic enzymes. As a result, norovirus is easily transmitted via **fecal-oral spread** (eg, foodborne, person-to-person via contaminated bodily fluids) and results in **outbreaks** in crowded settings (eg, schools, hospitals, cruise ships, nursing homes). The incubation period is 1-2 days; symptoms develop acutely and self-resolve within days. The diagnosis is typically based solely on clinical presentation, but polymerase chain reaction testing may be performed to confirm an outbreak.

(Choice A) Adenoviral gastroenteritis typically presents with fever and watery diarrhea. Outbreaks can occur, but these are far less common than with norovirus. Adenovirus more commonly causes pharyngoconjunctivitis and coryza (runny nose, nasal congestion).

(Choice B) Vomiting, high fever, and bloody diarrhea are typical of *Campylobacter jejuni* enteritis. Transmission occurs via oral contact with contaminated food (eg, poultry) or drinks. Outbreaks are not as common as those of viral etiology.

(Choice C) *Clostridium difficile* infection can result in asymptomatic carriers, pseudomembranous colitis, or fulminant colitis. Patients have watery diarrhea with or without blood, abdominal pain, fever, and leukocytosis. Prior antibiotic exposure (eg, penicillin, fluoroquinolones, clindamycin) is the most significant risk factor.

(Choice D) Enterotoxigenic *Escherichia coli* (ETEC), the most common cause of traveler's diarrhea, is prevalent in developing countries. The acute onset of nausea, vomiting, and watery, nonbloody diarrhea is typical of ETEC infection.

(Choice F) Gastroenteritis outbreaks can also occur in rotavirus infection, with a presentation similar to that of norovirus. However, the prevalence of rotavirus in developed countries has decreased dramatically since the introduction of routine childhood vaccination. Rotavirus is unlikely in children who are vaccinated or adults who likely have antibody protection from prior exposure during childhood.

(Choice G) *Salmonella typhi* can result in typhoid fever and presents with fever followed by abdominal pain and diarrhea and/or constipation. Severe complications (eg, hepatosplenomegaly, intestinal perforation, sepsis) occur in a minority of patients.

Educational objective:
Norovirus is the most common cause of viral gastroenteritis. Outbreaks (eg, schools, cruise ships, nursing homes) are common, and symptoms

with norovirus. Adenovirus more commonly causes pharyngoconjunctivitis and coryza (runny nose, nasal congestion).

(Choice B) Vomiting, high fever, and bloody diarrhea are typical of *Campylobacter jejuni* enteritis. Transmission occurs via oral contact with contaminated food (eg, poultry) or drinks. Outbreaks are not as common as those of viral etiology.

(Choice C) *Clostridium difficile* infection can result in asymptomatic carriers, pseudomembranous colitis, or fulminant colitis. Patients have watery diarrhea with or without blood, abdominal pain, fever, and leukocytosis. Prior antibiotic exposure (eg, penicillin, fluoroquinolones, clindamycin) is the most significant risk factor.

(Choice D) Enterotoxigenic *Escherichia coli* (ETEC), the most common cause of traveler's diarrhea, is prevalent in developing countries. The acute onset of nausea, vomiting, and watery, nonbloody diarrhea is typical of ETEC infection.

(Choice F) Gastroenteritis outbreaks can also occur in rotavirus infection, with a presentation similar to that of norovirus. However, the prevalence of rotavirus in developed countries has decreased dramatically since the introduction of routine childhood vaccination. Rotavirus is unlikely in children who are vaccinated or adults who likely have antibody protection from prior exposure during childhood.

(Choice G) *Salmonella typhi* can result in typhoid fever and presents with fever followed by abdominal pain and diarrhea and/or constipation. Severe complications (eg, hepatosplenomegaly, intestinal perforation, sepsis) occur in a minority of patients.

Educational objective:
Norovirus is the most common cause of viral gastroenteritis. Outbreaks (eg, schools, cruise ships, nursing homes) are common, and symptoms include vomiting and watery diarrhea.

References

- The burden of norovirus gastroenteritis: an important foodborne and healthcare-related infection.
- Evolution of norovirus.

Microbiology	Infectious Diseases	Acute diarrhea
Subject	System	Topic

Copyright © UWorld. All rights reserved.

Norovirus is the most common cause of **viral gastroenteritis**. Symptoms include diarrhea, **vomiting**, fever, malaise, and headache. The

Exhibit Display

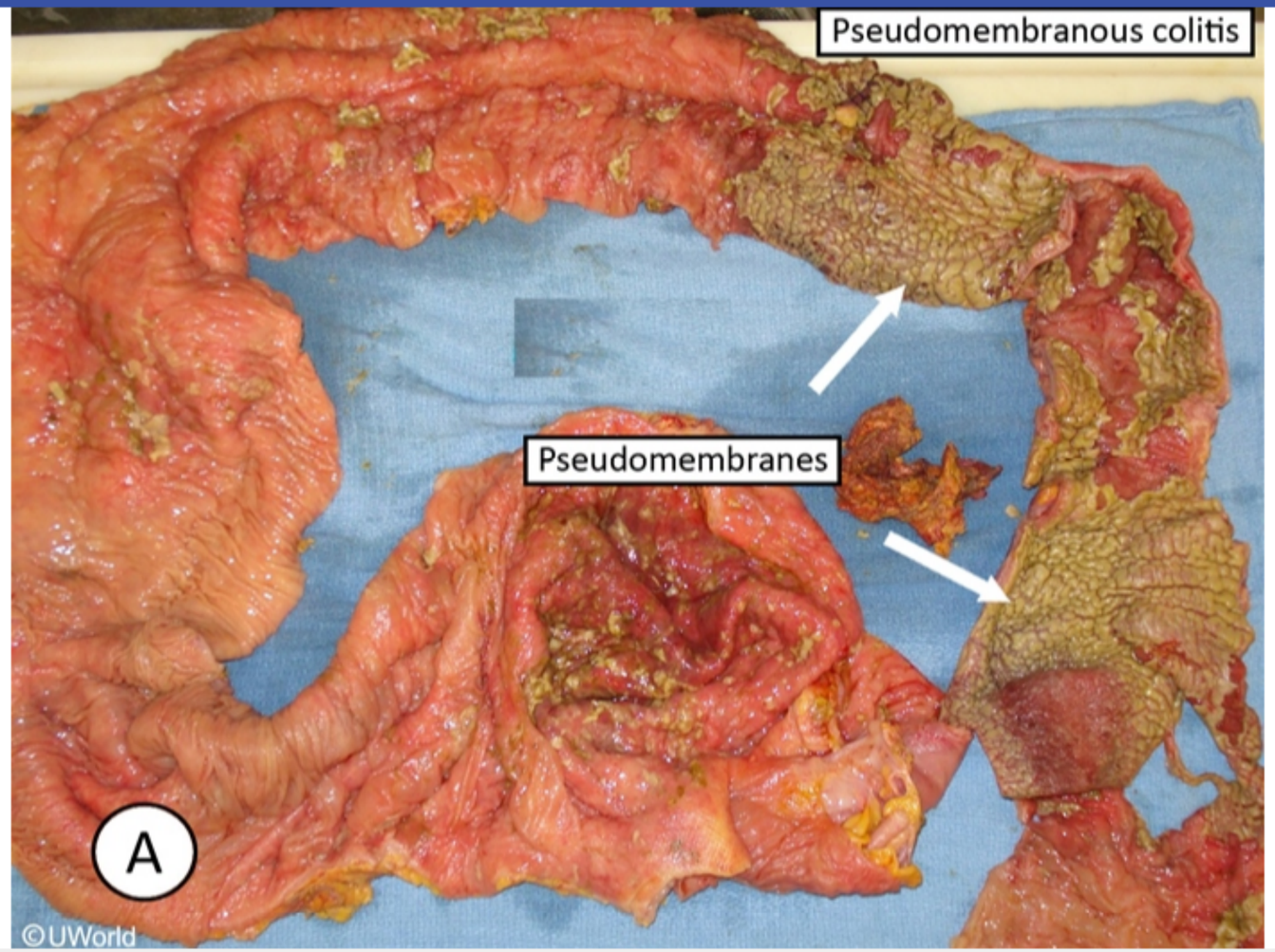

Zoom In | Zoom Out | Reset | Add To New Card | Existing Card

1
2
3
4
5
6
7
8
9
10
11
12
13
14
15
16
17
18
19
20
21
22
23
24
25
26
27
28
29
30
31

A 25-year-old primigravida has a stillbirth at 18 weeks gestation. Her only symptom during pregnancy was pain in both knees and feet, which she attributed to pregnancy-related weight gain and being "on my feet all day" as an elementary school teacher. The pain lasted approximately a week and resolved without medication. The patient was taking prenatal vitamins daily, and her prenatal care was appropriate. Fetal autopsy shows pleural effusion, pulmonary hypoplasia, and ascites. Infection with which of the following is the most likely etiology of the stillbirth?

A. Enveloped, double-stranded DNA virus

B. Enveloped, single-stranded RNA virus

C. Gram-positive coccus in chains

D. Nonenveloped, single-stranded DNA virus

E. Obligate intracellular protozoa

Submit

A 25-year-old primigravida has a stillbirth at 18 weeks gestation. Her only symptom during pregnancy was pain in both knees and feet, which she attributed to pregnancy-related weight gain and being "on my feet all day" as an elementary school teacher. The pain lasted approximately a week and resolved without medication. The patient was taking prenatal vitamins daily, and her prenatal care was appropriate. Fetal autopsy shows pleural effusion, pulmonary hypoplasia, and ascites. Infection with which of the following is the most likely etiology of the stillbirth?

A. Enveloped, double-stranded DNA virus (20%)

B. Enveloped, single-stranded RNA virus (22%)

C. Gram-positive coccus in chains (6%)

✓ D. Nonenveloped, single-stranded DNA virus (46%)

E. Obligate intracellular protozoa (4%)

Omitted
Correct answer
D

46%
Answered correctly

02 secs
Time Spent

02/20/2020
Last Updated

Explanation

Parvovirus is a nonenveloped **single-stranded (ss) DNA virus** with an increased incidence in children and teachers, as most individuals are infected during **school outbreaks**. Infection in adults can present with an acute, symmetric **arthralgia/arthritis** involving hands, wrists, knees, and/or feet, with or without rash.

Fetal infection with parvovirus can lead to **interruption of erythropoiesis**, causing **profound anemia** and congestive heart failure. Fetal congestive heart failure can cause pleural effusions, pericardial effusions, and **ascites**. The findings on fetal autopsy (pleural effusion with secondary pulmonary hypoplasia, and ascites) represent **fetal hydrops**.

Parvovirus is a nonenveloped **single-stranded (ss) DNA virus** with an increased incidence in children and teachers, as most individuals are infected during **school outbreaks**. Infection in adults can present with an acute, symmetric **arthralgia/arthritis** involving hands, wrists, knees, and/or feet, with or without rash.

Fetal infection with parvovirus can lead to **interruption of erythropoiesis**, causing **profound anemia** and congestive heart failure. Fetal congestive heart failure can cause pleural effusions, pericardial effusions, and **ascites**. The findings on fetal autopsy (pleural effusion with secondary pulmonary hypoplasia, and ascites) represent **fetal hydrops**.

Parvovirus is also responsible for erythema infectiosum ("fifth disease"), which presents with a "slapped cheek" appearance in children, and aplastic crisis in patients with sickle cell anemia.

(Choice A) Varicella zoster virus (VZV) and cytomegalovirus (CMV) are examples of enveloped, double-stranded DNA viruses. VZV exposure in the second trimester increases the risk of fetal varicella syndrome (presents as limb hypoplasia, microcephaly, chorioretinitis). Congenital CMV can cause jaundice, hepatosplenomegaly, and periventricular calcifications. Congenital CMV (and other TORCH infections), when severe, can also cause hydrops due to multiorgan failure. However, parvovirus is the most common infectious agent causing hydrops and is especially likely given the mother's history of transient arthralgias during pregnancy.

(Choice B) Rubella is an enveloped ssRNA virus. Congenital rubella infection characteristically causes cataracts, sensorineural deafness, and a "blueberry muffin" rash (purpuric lesions signify dermal erythropoiesis).

(Choice C) Group B streptococcus (GBS) is a gram-positive coccus that is present in chains and colonizes the female genital and gastrointestinal tracts. Fetuses exposed to GBS via the amniotic fluid during labor, or with rupture of membranes, can develop sepsis a few days after birth. GBS exposure does not cause hydrops fetalis.

(Choice E) Congenital toxoplasmosis leads to chorioretinitis, hydrocephalus, intracranial calcifications, microcephaly, and seizures. It is caused by an obligate intracellular protozoan, *Toxoplasma gondii*.

Educational objective:
Infection with parvovirus B19 (a nonenveloped single-stranded DNA virus) can cause arthralgia with or without rash in adults. An infected fetus may develop hydrops fetalis (severe anemia, heart failure, pleural effusions, pericardial effusions, and ascites).

References

Parvovirus is also responsible for erythema infectiosum ("fifth disease"), which presents with a "slapped cheek" appearance in children, and aplastic crisis in patients with sickle cell anemia.

(Choice A) Varicella zoster virus (VZV) and cytomegalovirus (CMV) are examples of enveloped, double-stranded DNA viruses. VZV exposure in the second trimester increases the risk of fetal varicella syndrome (presents as limb hypoplasia, microcephaly, chorioretinitis). Congenital CMV can cause jaundice, hepatosplenomegaly, and periventricular calcifications. Congenital CMV (and other TORCH infections), when severe, can also cause hydrops due to multiorgan failure. However, parvovirus is the most common infectious agent causing hydrops and is especially likely given the mother's history of transient arthralgias during pregnancy.

(Choice B) Rubella is an enveloped ssRNA virus. Congenital rubella infection characteristically causes cataracts, sensorineural deafness, and a "blueberry muffin" rash (purpuric lesions signify dermal erythropoiesis).

(Choice C) Group B streptococcus (GBS) is a gram-positive coccus that is present in chains and colonizes the female genital and gastrointestinal tracts. Fetuses exposed to GBS via the amniotic fluid during labor, or with rupture of membranes, can develop sepsis a few days after birth. GBS exposure does not cause hydrops fetalis.

(Choice E) Congenital toxoplasmosis leads to chorioretinitis, hydrocephalus, intracranial calcifications, microcephaly, and seizures. It is caused by an obligate intracellular protozoan, *Toxoplasma gondii*.

Educational objective:
Infection with parvovirus B19 (a nonenveloped single-stranded DNA virus) can cause arthralgia with or without rash in adults. An infected fetus may develop hydrops fetalis (severe anemia, heart failure, pleural effusions, pericardial effusions, and ascites).

References

- Parvovirus B19 during pregnancy: a review.
- Parvovirus B19 infection in human pregnancy.

Microbiology	Infectious Diseases	Parvovirus
Subject	System	Topic

Copyright © UWorld. All rights reserved.

Parvovirus is also responsible for erythema infectiosum ("fifth disease"), which presents with a "slapped cheek" appearance in children, and aplastic crisis in patients w

(Choice A) Varicella zost e in the second trimester incre can cause jaundice, hepat also cause hydrops due to ly given the mother's history

(Choice B) Rubella is an d a "blueberry muffin" rash (pu

(Choice C) Group B strep tinal tracts. Fetuses exposed t BS exposure does not cause

(Choice E) Congenital to ed by an obligate intracellular

Educational objective:
Infection with parvovirus B s may develop hydrops feta

References

- Parvovirus B19 during
- Parvovirus B19 infecti

Microbiology Subject | Infect System | Topic

Copyright © UWorld. All rights reserved.

Exhibit Display

Congenital TORCH infections

Organism	Etiology	Clinical features
Toxoplasmosis	Obligate intracellular protozoan *Toxoplasma gondii*	Chorioretinitis, intracranial calcifications, hydrocephalus
Other (VZV, parvovirus)	• VZV: dsDNA virus • Parvovirus: ssDNA virus • Syphilis: spirochete *Treponema pallidum*	• VZV: limb hypoplasia, cutaneous scarring, cataracts, chorioretinitis • Parvovirus: hydrops fetalis • Syphilis: "snuffles," hepatomegaly, skeletal anomalies
Rubella	ssRNA virus	Sensorineural deafness, cataracts, "blueberry muffin" rash, heart defects, hepatosplenomegaly
CMV	dsDNA virus	Sensorineural deafness, periventricular calcifications, jaundice, hepatosplenomegaly, chorioretinitis
HSV	dsDNA virus	Cutaneous vesicles, lesions, scarring

CMV = cytomegalovirus; **ds** = double-stranded; **HSV** = herpes simplex virus; **ss** = single-stranded; **VZV** = varicella zoster virus.

Add To New Card | Existing Card

1
2
3
4
5
6
7
8
9
10
11
12
13
14
15
16
17
18
19
20
21
22
23
24
25
26
27
28
29
30
31

A 30-year-old man is admitted to the intensive care unit after his wife found him unconscious at home. She says that he has lost a significant amount of weight recently despite no significant change in dietary habits. Laboratory studies show a serum pH of 7.1 and positive serum ketones. His mucus membranes are extremely dry. Treatment is initiated, and the patient's condition improves. However, he now has fever, headache, and eye pain. Examination of the nasal cavity shows a black necrotic eschar adherent to the inferior turbinate. Which of the following procedures would likely reveal the pathogen responsible for the fever, facial pain, and eschar?

A. Blood cultures
B. Lumbar puncture
C. Mucosal biopsy
D. Ophthalmoscopy
E. Serologic testing
F. Skin hypersensitivity test

Submit

A 30-year-old man is admitted to the intensive care unit after his wife found him unconscious at home. She says that he has lost a significant amount of weight recently despite no significant change in dietary habits. Laboratory studies show a serum pH of 7.1 and positive serum ketones. His mucus membranes are extremely dry. Treatment is initiated, and the patient's condition improves. However, he now has fever, headache, and eye pain. Examination of the nasal cavity shows a black necrotic eschar adherent to the inferior turbinate. Which of the following procedures would likely reveal the pathogen responsible for the fever, facial pain, and eschar?

- A. Blood cultures (19%)
- B. Lumbar puncture (7%)
- ✓ C. Mucosal biopsy (61%)
- D. Ophthalmoscopy (1%)
- E. Serologic testing (9%)
- F. Skin hypersensitivity test (1%)

Omitted
Correct answer
C

61%
Answered correctly

02 secs
Time Spent

03/20/2020
Last Updated

Explanation

Facial pain, headache, and nasal eschar in a patient with likely diabetic ketoacidosis (pH 7.1, positive ketones, and dry mucous membranes in a young patient with unintended weight loss) are highly suggestive of **mucormycosis**, caused by *Mucor* or *Rhizopus*, among others. Most cases are **rhinocerebral**. The infection (acquired by spore inhalation) ascends from the nasal passage to the sinuses/orbits and then sometimes to the brain, leading to confusion, neurological deficits, and death. The increased incidence of mucormycosis in **diabetics** could be due to the ketone

1
2
3
4
5
6
7
8
9
10
11
12
13
14
15
16
17
18
19
20
21
22
23
24
25
26
27
28
29
30
31

Facial pain, headache, and nasal eschar in a patient with likely diabetic ketoacidosis (pH 7.1, positive ketones, and dry mucous membranes in a young patient with unintended weight loss) are highly suggestive of **mucormycosis**, caused by *Mucor* or *Rhizopus*, among others. Most cases are **rhinocerebral**. The infection (acquired by spore inhalation) ascends from the nasal passage to the sinuses/orbits and then sometimes to the brain, leading to confusion, neurological deficits, and death. The increased incidence of mucormycosis in **diabetics** could be due to the ketone reductase activity of *Rhizopus* (allowing it to survive in an acidotic, hyperglycemic environment) and possibly to the release of iron from binding proteins during ketoacidosis (facilitating *Rhizopus* growth).

Histologic examination is necessary for diagnosis. The fungi appear as broad ribbon-like nonseptate hyphae with right-angle branching. Tissue invasion is seen along blood vessels; vascular thrombosis and tissue necrosis can occur. A black necrotic **eschar** in the nasal cavity is characteristic. Management includes amphotericin B and surgical debridement. Mucormycosis (commonly seen in diabetics) must be differentiated from invasive aspergillosis causing rhinosinusitis (commonly seen in neutropenic patients). On light microscopy, *Aspergillus* is seen as septate narrow hyphae with sharp-angle branching.

(Choice A) Blood cultures are usually negative in mucormycosis. They can be useful in diagnosing candidemia (clinical manifestations range from low-grade fever to multiorgan failure, occasionally with characteristic chorioretinitis and clustered pustular skin lesions).

(Choice B) Lumbar puncture helps to diagnose cryptococcal meningitis, a fungal infection that typically has an indolent presentation and usually affects patients with AIDS. India ink staining of cerebrospinal fluid reveals the classic encapsulated yeast of *Cryptococcus neoformans*.

(Choice D) Ophthalmoscopy is useful for the diagnosis of *Candida* endophthalmitis, which typically presents with impaired visual acuity.

(Choices E and F) Serologic testing is important in the diagnosis of allergic bronchopulmonary aspergillosis (ABPA), where increased titers of IgE and antibodies to *Aspergillus fumigatus* are seen. Skin hypersensitivity testing is also useful. However, the typical presentation of ABPA is recurrent episodes of fever and bronchial obstruction in a patient with asthma.

Educational objective:
Facial pain, headache, and black necrotic eschar in the nasal cavity in a patient with diabetic ketoacidosis are highly suggestive of mucormycosis. Histologic examination of the affected tissue is necessary to confirm the diagnosis. The fungi show broad nonseptate hyphae with right-angle branching. Treatment consists of surgical debridement and antifungal therapy.

1
2
3
4
5
6
7
8
9
10
11
12
13
14
15
16
17
18
19
20
21
22
23
24
25
26
27
28
29
30
31

proteins during ketoacidosis (facilitating *Rhizopus* growth).

Histologic examination is necessary for diagnosis. The fungi appear as broad ribbon-like nonseptate hyphae with right-angle branching. Tissue invasion is seen along blood vessels; vascular thrombosis and tissue necrosis can occur. A black necrotic **eschar** in the nasal cavity is characteristic. Management includes amphotericin B and surgical debridement. Mucormycosis (commonly seen in diabetics) must be differentiated from invasive aspergillosis causing rhinosinusitis (commonly seen in neutropenic patients). On light microscopy, *Aspergillus* is seen as septate narrow hyphae with sharp-angle branching.

(Choice A) Blood cultures are usually negative in mucormycosis. They can be useful in diagnosing candidemia (clinical manifestations range from low-grade fever to multiorgan failure, occasionally with characteristic chorioretinitis and clustered pustular skin lesions).

(Choice B) Lumbar puncture helps to diagnose cryptococcal meningitis, a fungal infection that typically has an indolent presentation and usually affects patients with AIDS. India ink staining of cerebrospinal fluid reveals the classic encapsulated yeast of *Cryptococcus neoformans*.

(Choice D) Ophthalmoscopy is useful for the diagnosis of *Candida* endophthalmitis, which typically presents with impaired visual acuity.

(Choices E and F) Serologic testing is important in the diagnosis of allergic bronchopulmonary aspergillosis (ABPA), where increased titers of IgE and antibodies to *Aspergillus fumigatus* are seen. Skin hypersensitivity testing is also useful. However, the typical presentation of ABPA is recurrent episodes of fever and bronchial obstruction in a patient with asthma.

Educational objective:
Facial pain, headache, and black necrotic eschar in the nasal cavity in a patient with diabetic ketoacidosis are highly suggestive of mucormycosis. Histologic examination of the affected tissue is necessary to confirm the diagnosis. The fungi show broad nonseptate hyphae with right-angle branching. Treatment consists of surgical debridement and antifungal therapy.

References

- Novel perspectives on mucormycosis: pathophysiology, presentation, and management.

Microbiology	Infectious Diseases	Mucormycosis
Subject	System	Topic

Copyright © UWorld. All rights reserved.

proteins during ketoacidosis (facilitating Rhizopus growth).

Exhibit Display

Abdominal mucormycosis

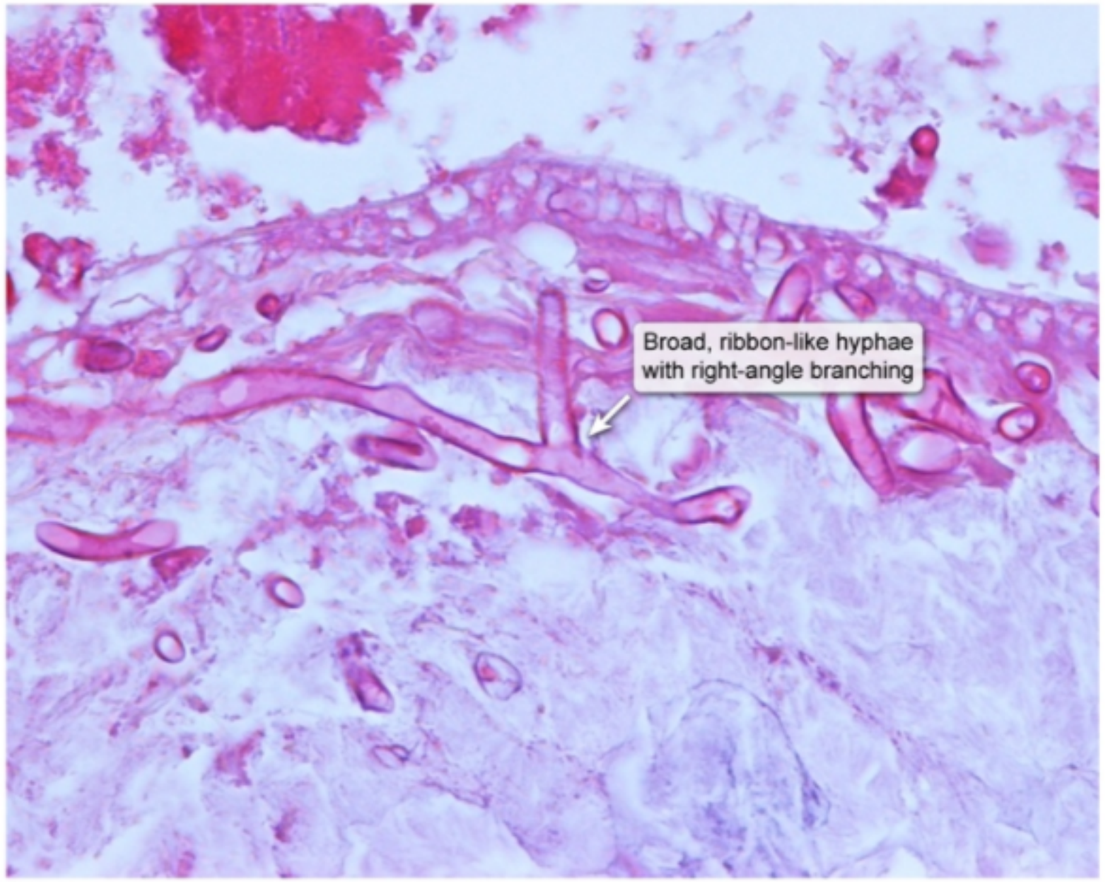

©UWorld

Zoom In | Zoom Out | Reset | Add To New Card | Existing Card

proteins during keratinization (facilitating Anizopus growth).

Exhibit Display

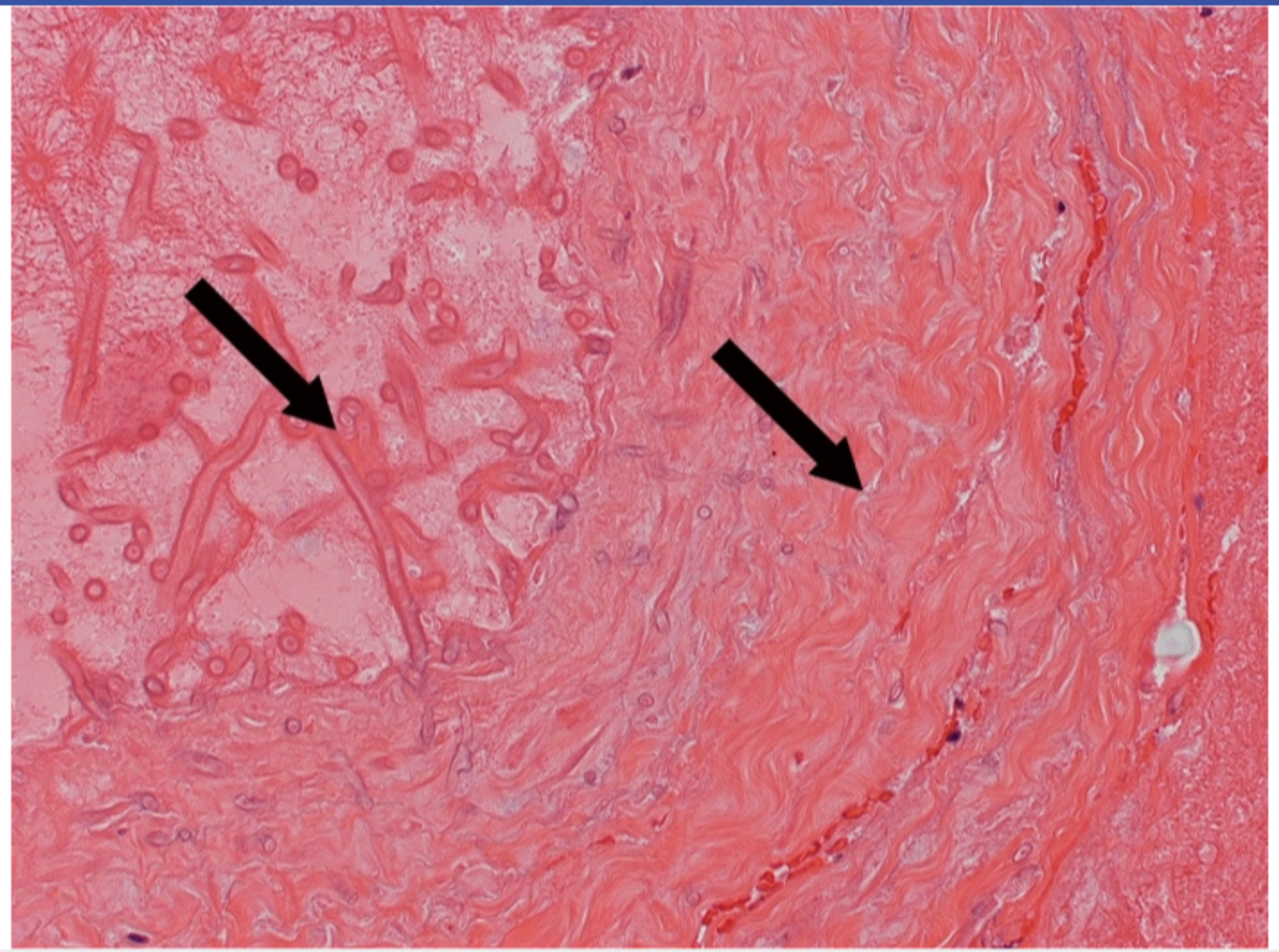

Zoom In | Zoom Out | Reset | Add To New Card | Existing Card

1
2
3
4
5
6
7
8
9
10
11
12
13
14
15
16
17
18
19
20
21
22
23
24
25
26
27
28
29
30
31

A 12-year-old boy is brought to the emergency department by paramedics after being found unresponsive at home. He had 24 hours of headache, nausea, and fever, which his parents were treating with acetaminophen. His temperature is 39.6 C (103.4 F). Physical examination reveals neck stiffness. Lumbar puncture is performed. Analysis of cerebrospinal fluid shows marked pleocytosis, and Gram stain shows gram-negative cocci in pairs. The parents are concerned about their younger son, who shares a bedroom with the patient. Which of the following is the most appropriate management of this patient's household contacts?

A. Immediate vaccination

B. Observation only

C. Prophylactic penicillin

D. Prophylactic rifampin

E. Prophylactic sulfamethoxazole

Submit

1
2
3
4
5
6
7
8
9
10
11
12
13
14
15
16
17
18
19
20
21
22
23
24
25
26
27
28
29
30
31

A 12-year-old boy is brought to the emergency department by paramedics after being found unresponsive at home. He had 24 hours of headache, nausea, and fever, which his parents were treating with acetaminophen. His temperature is 39.6 C (103.4 F). Physical examination reveals neck stiffness. Lumbar puncture is performed. Analysis of cerebrospinal fluid shows marked pleocytosis, and Gram stain shows gram-negative cocci in pairs. The parents are concerned about their younger son, who shares a bedroom with the patient. Which of the following is the most appropriate management of this patient's household contacts?

A. Immediate vaccination (7%)

B. Observation only (4%)

C. Prophylactic penicillin (8%)

✓ D. Prophylactic rifampin (76%)

E. Prophylactic sulfamethoxazole (3%)

Omitted
Correct answer
D

76%
Answered correctly

02 secs
Time Spent

03/01/2020
Last Updated

Explanation

This patient's presentation and the finding of gram-negative diplococci highly suggest meningitis due to ***Neisseria meningitidis***. *N meningitidis* is transmitted by direct contact with contaminated **respiratory secretions** or aerosolized droplets. As a result, people with **close** or **intimate** contact (eg, household contacts, kissing contacts, health care workers who directly contacted secretions) are at markedly increased risk of meningococcal infection. **Antibiotic** chemoprophylaxis can prevent these secondary cases if given promptly. A history of meningococcal vaccination does not preclude the need for antibiotic chemoprophylaxis.

1
2
3
4
5
6
7
8
9
10
11
12
13
14
15
16
17
18
19
20
21
22
23
24
25
26
27
28
29
30
31

Explanation

This patient's presentation and the finding of gram-negative diplococci highly suggest meningitis due to ***Neisseria meningitidis***. *N meningitidis* is transmitted by direct contact with contaminated **respiratory secretions** or aerosolized droplets. As a result, people with **close** or **intimate** contact (eg, household contacts, kissing contacts, health care workers who directly contacted secretions) are at markedly increased risk of meningococcal infection. **Antibiotic** chemoprophylaxis can prevent these secondary cases if given promptly. A history of meningococcal vaccination does not preclude the need for antibiotic chemoprophylaxis.

Of the listed agents, **rifampin** is the only effective choice. Rifampin penetrates well into all body compartments, including the upper respiratory tract, and will eliminate nasopharyngeal colonization. Other effective agents include ciprofloxacin (not routinely used in children due to concerns about connective tissue injury) and intramuscular ceftriaxone, which is effective but not widely used due to the painful mode of administration. Chemoprophylaxis should be given as soon as possible, preferably within 24 hours of diagnosis.

(Choice A) Vaccination is an important public health strategy for control of meningococcal disease in general, but does not play a role in post-exposure prophylaxis. Immunity following a post-exposure vaccination does not occur in time to prevent disease.

(Choice B) A person's risk for infection is 500-1,000 times greater following an exposure to a meningococcal disease patient, and disease onset can be rapid. Therefore, observation alone is not an appropriate strategy for exposed close contacts.

(Choice C) Although penicillin can be used for treatment of susceptible meningococcal infections, it has not been shown to eliminate nasal carriage or prevent secondary cases. Therefore, it should not be used for chemoprophylaxis.

(Choice E) Sulfamethoxazole was the first agent to be used as chemoprophylaxis for meningococcal disease. However, it is no longer an effective agent due to widespread resistance.

Educational objective:
Rifampin is the most frequently used agent for chemoprophylaxis of meningococcal disease. Persons with exposure to the respiratory secretions of a patient with meningococcal disease require chemoprophylaxis. Vaccination is an important public health strategy but is not useful for post-exposure prophylaxis.

References

- Meningococcal disease in childhood: epidemiology, clinical features and prevention.

1
2
3
4
5
6
7
8
9
10
11
12
13
14
15
16
17
18
19
20
21
22
23
24
25
26
27
28
29
30
31

vaccination does not preclude the need for antibiotic chemoprophylaxis.

Of the listed agents, **rifampin** is the only effective choice. Rifampin penetrates well into all body compartments, including the upper respiratory tract, and will eliminate nasopharyngeal colonization. Other effective agents include ciprofloxacin (not routinely used in children due to concerns about connective tissue injury) and intramuscular ceftriaxone, which is effective but not widely used due to the painful mode of administration. Chemoprophylaxis should be given as soon as possible, preferably within 24 hours of diagnosis.

(Choice A) Vaccination is an important public health strategy for control of meningococcal disease in general, but does not play a role in post-exposure prophylaxis. Immunity following a post-exposure vaccination does not occur in time to prevent disease.

(Choice B) A person's risk for infection is 500-1,000 times greater following an exposure to a meningococcal disease patient, and disease onset can be rapid. Therefore, observation alone is not an appropriate strategy for exposed close contacts.

(Choice C) Although penicillin can be used for treatment of susceptible meningococcal infections, it has not been shown to eliminate nasal carriage or prevent secondary cases. Therefore, it should not be used for chemoprophylaxis.

(Choice E) Sulfamethoxazole was the first agent to be used as chemoprophylaxis for meningococcal disease. However, it is no longer an effective agent due to widespread resistance.

Educational objective:
Rifampin is the most frequently used agent for chemoprophylaxis of meningococcal disease. Persons with exposure to the respiratory secretions of a patient with meningococcal disease require chemoprophylaxis. Vaccination is an important public health strategy but is not useful for post-exposure prophylaxis.

References

- Meningococcal disease in childhood: epidemiology, clinical features and prevention.

Microbiology	Infectious Diseases	Meningitis
Subject	System	Topic

Copyright © UWorld. All rights reserved.

1
2
3
4
5
6
7
8
9
10
11
12
13
14
15
16
17
18
19
20
21
22
23
24
25
26
27
28
29
30
31

A 12-year-old girl is brought to an urgent care clinic due to nausea, vomiting, and crampy abdominal pain 3 hours after a summer cookout in a park, where she consumed potato salad, coleslaw, and a hamburger. Two other children who attended the event also had similar symptoms. She has no chronic medical conditions and previously felt well. On examination, the patient is afebrile, and the abdomen is soft and nontender. Her symptoms quickly resolve with supportive care. Which of the following strategies would have been most effective in preventing this patient's illness?

A. Avoiding close contact with a person with similar symptoms

B. Cooking meat products to safe minimum temperatures

C. Keeping prepared foods refrigerated while storing

D. Performing adequate treatment of drinking water

E. Washing hands thoroughly before consuming a meal

Submit

A 12-year-old girl is brought to an urgent care clinic due to nausea, vomiting, and crampy abdominal pain 3 hours after a summer cookout in a park, where she consumed potato salad, coleslaw, and a hamburger. Two other children who attended the event also had similar symptoms. She has no chronic medical conditions and previously felt well. On examination, the patient is afebrile, and the abdomen is soft and nontender. Her symptoms quickly resolve with supportive care. Which of the following strategies would have been most effective in preventing this patient's illness?

- A. Avoiding close contact with a person with similar symptoms (0%)
- B. Cooking meat products to safe minimum temperatures (12%)
- ✓ C. Keeping prepared foods refrigerated while storing (82%)
- D. Performing adequate treatment of drinking water (0%)
- E. Washing hands thoroughly before consuming a meal (3%)

Omitted
Correct answer
C

82%
Answered correctly

02 secs
Time Spent

05/20/2020
Last Updated

Explanation

Enterotoxigenic *Staphylococcus aureus* produces a heat-stable enterotoxin that is a common cause of foodborne illness. This pathogen is typically introduced into high-risk foods (eg, mayonnaise-based salads, eggs, dairy, previously cooked meats) during improper food handling by an asymptomatic carrier. Storage at **room temperature** for extended periods allows the organism to quickly proliferate and generate enterotoxin. Individuals then ingest the **preformed enterotoxin** and become rapidly ill with nausea, **vomiting**, abdominal pain, and, occasionally, fever and mild diarrhea. Symptoms quickly resolve with supportive care. Multiple individuals are often affected due to the consumption of the same food at

Explanation

Enterotoxigenic *Staphylococcus aureus* produces a heat-stable enterotoxin that is a common cause of foodborne illness. This pathogen is typically introduced into high-risk foods (eg, mayonnaise-based salads, eggs, dairy, previously cooked meats) during improper food handling by an asymptomatic carrier. Storage at **room temperature** for extended periods allows the organism to quickly proliferate and generate enterotoxin. Individuals then ingest the **preformed enterotoxin** and become rapidly ill with nausea, **vomiting**, abdominal pain, and, occasionally, fever and mild diarrhea. Symptoms quickly resolve with supportive care. Multiple individuals are often affected due to the consumption of the same food at a picnic, party, or potluck.

Staphylococcal foodborne illness can be prevented by washing hands thoroughly with soap and water prior to preparing food (prevents contamination) and ensuring **proper refrigerated food storage** when food will not be consumed within 2 hours of preparation (prevents bacterial proliferation/enterotoxin production).

(Choice A) Close contact with an individual who has rotavirus infection can lead to the transmission of the virus with subsequent acute infectious diarrhea (particularly in young children [age <5]). Staphylococcal gastroenteritis occurs when a preformed toxin is ingested in food; person-to-person transmission does not occur.

(Choice B) Enterohemorrhagic *Escherichia coli* is typically transmitted due to eating undercooked, contaminated ground beef. Manifestations typically begin 3-4 days (not hours) after ingestion and include toxin-mediated (Shiga toxin) colitis with bloody stools; some patients may also develop hemolytic uremic syndrome.

(Choice D) Treatment of drinking water can prevent giardia infection, which usually causes foul-smelling, watery diarrhea 7-10 days after transmission.

(Choice E) Washing hands prior to eating can prevent the transmission of a wide range of pathogens. Hand washing would not be protective against enterotoxins present in food.

Educational objective:
Staphylococcal foodborne illness is due to the consumption of a preformed enterotoxin in contaminated food. Most cases can be prevented by washing hands thoroughly prior to food preparation (prevents contamination) and ensuring proper refrigerated storage (prevents bacterial proliferation/enterotoxin production).

Individuals then ingest the **preformed enterotoxin** and become rapidly ill with nausea, **vomiting**, abdominal pain, and, occasionally, fever and mild diarrhea. Symptoms quickly resolve with supportive care. Multiple individuals are often affected due to the consumption of the same food at a picnic, party, or potluck.

Staphylococcal foodborne illness can be prevented by washing hands thoroughly with soap and water prior to preparing food (prevents contamination) and ensuring **proper refrigerated food storage** when food will not be consumed within 2 hours of preparation (prevents bacterial proliferation/enterotoxin production).

(Choice A) Close contact with an individual who has rotavirus infection can lead to the transmission of the virus with subsequent acute infectious diarrhea (particularly in young children [age <5]). Staphylococcal gastroenteritis occurs when a preformed toxin is ingested in food; person-to-person transmission does not occur.

(Choice B) Enterohemorrhagic *Escherichia coli* is typically transmitted due to eating undercooked, contaminated ground beef. Manifestations typically begin 3-4 days (not hours) after ingestion and include toxin-mediated (Shiga toxin) colitis with bloody stools; some patients may also develop hemolytic uremic syndrome.

(Choice D) Treatment of drinking water can prevent giardia infection, which usually causes foul-smelling, watery diarrhea 7-10 days after transmission.

(Choice E) Washing hands prior to eating can prevent the transmission of a wide range of pathogens. Hand washing would not be protective against enterotoxins present in food.

Educational objective:
Staphylococcal foodborne illness is due to the consumption of a preformed enterotoxin in contaminated food. Most cases can be prevented by washing hands thoroughly prior to food preparation (prevents contamination) and ensuring proper refrigerated storage (prevents bacterial proliferation/enterotoxin production).

Microbiology	Infectious Diseases	Foodborne illness
Subject	System	Topic

Copyright © UWorld. All rights reserved.

1
2
3
4
5
6
7
8
9
10
11
12
13
14
15
16
17
18
19
20
21
22
23
24
25
26
27
28
29
30
31

A 65-year-old man comes to the emergency department with fevers and malaise over the last 48 hours. He initially experienced fevers and chills, which subsequently progressed to fatigue to the point that he had difficulty performing routine tasks this morning. He has also had a mild headache. The patient lives in eastern Massachusetts with his wife. He is retired and spends time gardening and swimming at a local public pool. He traveled to Thailand 2 years ago with his family and to Florida 2 months ago. His temperature is 38.9 C (102 F), blood pressure is 122/70 mm Hg, and pulse is 114/min and regular. The oropharynx is dry without lesions. Lung examination reveals coarse crackles bilaterally. The patient's abdomen is soft and mildly tender throughout with palpable splenomegaly. He has no rash or open wounds. A peripheral blood smear (as shown in the exhibit) is performed. What is the most likely source of this infection?

A. *Aedes* mosquito
B. Brown recluse spider
C. Dog bite
D. Freshwater consumption
E. *Ixodes* tick
F. Scratch from a garden bush
G. Spore inhalation

Submit

1
2
3
4
5
6
7
8
9
10
11
12
13
14
15
16
17
18
19
20
21
22
23
24
25
26
27
28
29
30
31

Exhibit Display

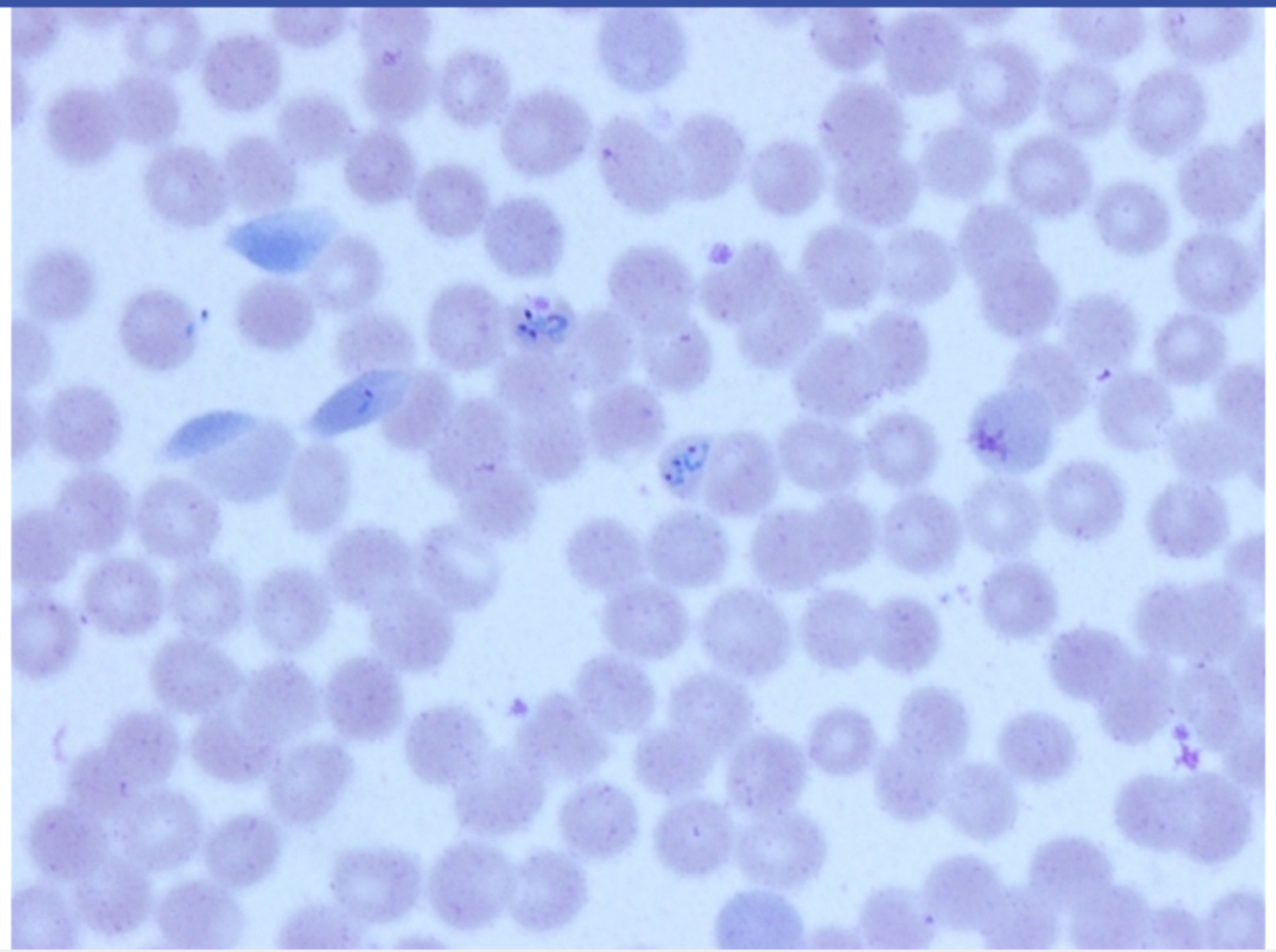

Zoom In | Zoom Out | Reset | Add To New Card | Existing Card

1
2
3
4
5
6
7
8
9
10
11
12
13
14
15
16
17
18
19
20
21
22
23
24
25
26
27
28
29
30
31

A 65-year-old man comes to the emergency department with fevers and malaise over the last 48 hours. He initially experienced fevers and chills, which subsequently progressed to fatigue to the point that he had difficulty performing routine tasks this morning. He has also had a mild headache. The patient lives in eastern Massachusetts with his wife. He is retired and spends time gardening and swimming at a local public pool. He traveled to Thailand 2 years ago with his family and to Florida 2 months ago. His temperature is 38.9 C (102 F), blood pressure is 122/70 mm Hg, and pulse is 114/min and regular. The oropharynx is dry without lesions. Lung examination reveals coarse crackles bilaterally. The patient's abdomen is soft and mildly tender throughout with palpable splenomegaly. He has no rash or open wounds. A peripheral blood smear (as shown in the exhibit) is performed. What is the most likely source of this infection?

A. *Aedes* mosquito (34%)
B. Brown recluse spider (0%)
C. Dog bite (0%)
D. Freshwater consumption (6%)
✓ E. *Ixodes* tick (47%)
F. Scratch from a garden bush (5%)
G. Spore inhalation (5%)

Omitted
Correct answer
E

47%
Answered correctly

09 secs
Time Spent

01/28/2020
Last Updated

Explanation

1
2
3
4
5
6
7
8
9
10
11
12
13
14
15
16
17
18
19
20
21
22
23
24
25
26
27
28
29
30
31

Babesiosis	
Epidemiology	• Agent: *Babesia microti* • Vector: *Ixodes scapularis* **tick** (same for Lyme disease & HGA) • Geographic distribution: Northeastern United States
Clinical manifestations	• Signs & symptoms: Fevers, fatigue, myalgias, headache, **flulike symptoms** (if **severe**: ARDS, CHF, DIC, splenic rupture) • Laboratory studies: **Anemia, thrombocytopenia**, ↑LFTs
Diagnosis	• Thin blood smear (Wright/Giemsa stains): **Intraerythrocytic** pleomorphic **ring forms** (occasional "Maltese crosses")

ARDS = acute respiratory distress syndrome; **CHF** = congestive heart failure; **DIC** = disseminated intravascular coagulation; **HGA** = human granulocytic anaplasmosis; **LFTs** = liver function tests.

©UWorld

This patient with an acute febrile illness has a peripheral blood smear showing intraerythrocytic ring inclusions. Parasites that can potentially cause disease in red blood cells include *Plasmodium* (malaria) and *Babesia* (babesiosis). In this patient, the epidemiology - residence in **northeastern United States**, outdoor exposure in the summer - is suggestive of **babesiosis**. This organism is transmitted by the *Ixodes scapularis* tick, which is also a vector for *Borrelia burgdorferi*, the bacteria that cause Lyme disease.

(Choice A) *Aedes* is the vector for dengue fever and chikungunya, which have been diagnosed in Florida but have different presentations (eg, rash, arthralgias) and a short incubation period (<14 days). Malaria is transmitted by *Anopheles* and is endemic in Thailand; although it can also cause intraerythrocytic ring inclusions, it has a typical incubation period of weeks (this patient visited Thailand years ago).

(Choice B) Brown recluse spider bites can cause fever and malaise and less commonly anemia; however, they would not be associated with intraerythrocytic organisms.

(Choice C) Dog bites can be associated with a variety of organisms causing soft-tissue infection, including *Pasteurella*, streptococci, and

1
2
3
4
5
6
7
8
9
10
11
12
13
14
15
16
17
18
19
20
21
22
23
24
25
26
27
28
29
30
31

This patient with an acute febrile illness has a peripheral blood smear showing intraerythrocytic ring inclusions. Parasites that can potentially cause disease in red blood cells include *Plasmodium* (malaria) and *Babesia* (babesiosis). In this patient, the epidemiology - residence in **northeastern United States**, outdoor exposure in the summer - is suggestive of **babesiosis**. This organism is transmitted by the *Ixodes scapularis* tick, which is also a vector for *Borrelia burgdorferi*, the bacteria that cause Lyme disease.

(Choice A) *Aedes* is the vector for dengue fever and chikungunya, which have been diagnosed in Florida but have different presentations (eg, rash, arthralgias) and a short incubation period (<14 days). Malaria is transmitted by *Anopheles* and is endemic in Thailand; although it can also cause intraerythrocytic ring inclusions, it has a typical incubation period of weeks (this patient visited Thailand years ago).

(Choice B) Brown recluse spider bites can cause fever and malaise and less commonly anemia; however, they would not be associated with intraerythrocytic organisms.

(Choice C) Dog bites can be associated with a variety of organisms causing soft-tissue infection, including *Pasteurella*, streptococci, and staphylococci.

(Choice D) Freshwater consumption can be associated with intraintestinal bacterial and parasitic infections such as cryptosporidiosis and giardiasis. However, these infections typically cause gastrointestinal illnesses.

(Choice F) Exposure to plants and soil can be associated with bacterial infections, including *Nocardia* and fungal infections such as sporotrichosis. These most commonly present as soft-tissue infections; systemic infections are rare in immunocompetent patients.

(Choice G) Fungal spore inhalation can lead to pulmonary infections, including histoplasmosis and blastomycosis. These organisms are not endemic to the northeastern United States and are not associated with intraerythrocytic organisms.

Educational objective:
Babesiosis should be considered in patients with febrile illness who reside in geographic areas where they are exposed to *Ixodes* ticks. Diagnosis can be established with the identification of intraerythrocytic organisms on peripheral blood smear.

References

- Babesiosis.
- Human babesiosis.

1
2
3
4
5
6
7
8
9
10
11
12
13
14
15
16
17
18
19
20
21
22
23
24
25
26
27
28
29
30
31

Exhibit Display

Babesiosis Babesiosis: Babesia microti

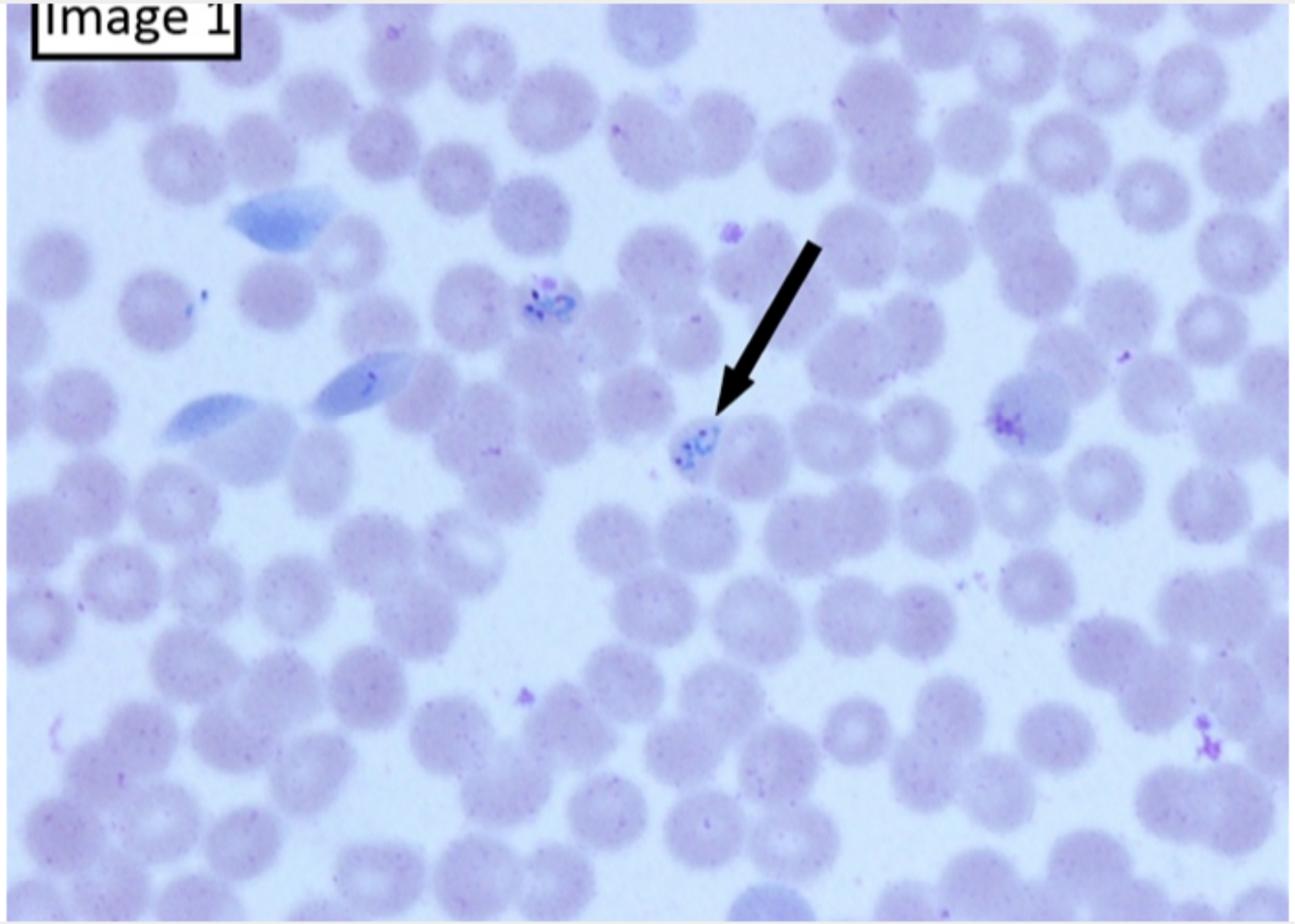

Zoom In Zoom Out Reset Add To New Card | Existing Card

1
2
3
4
5
6
7
8
9
10
11
12
13
14
15
16
17
18
19
20
21
22
23
24
25
26
27
28
29
30
31

Exhibit Display

Babesiosis Babesiosis: Babesia microti

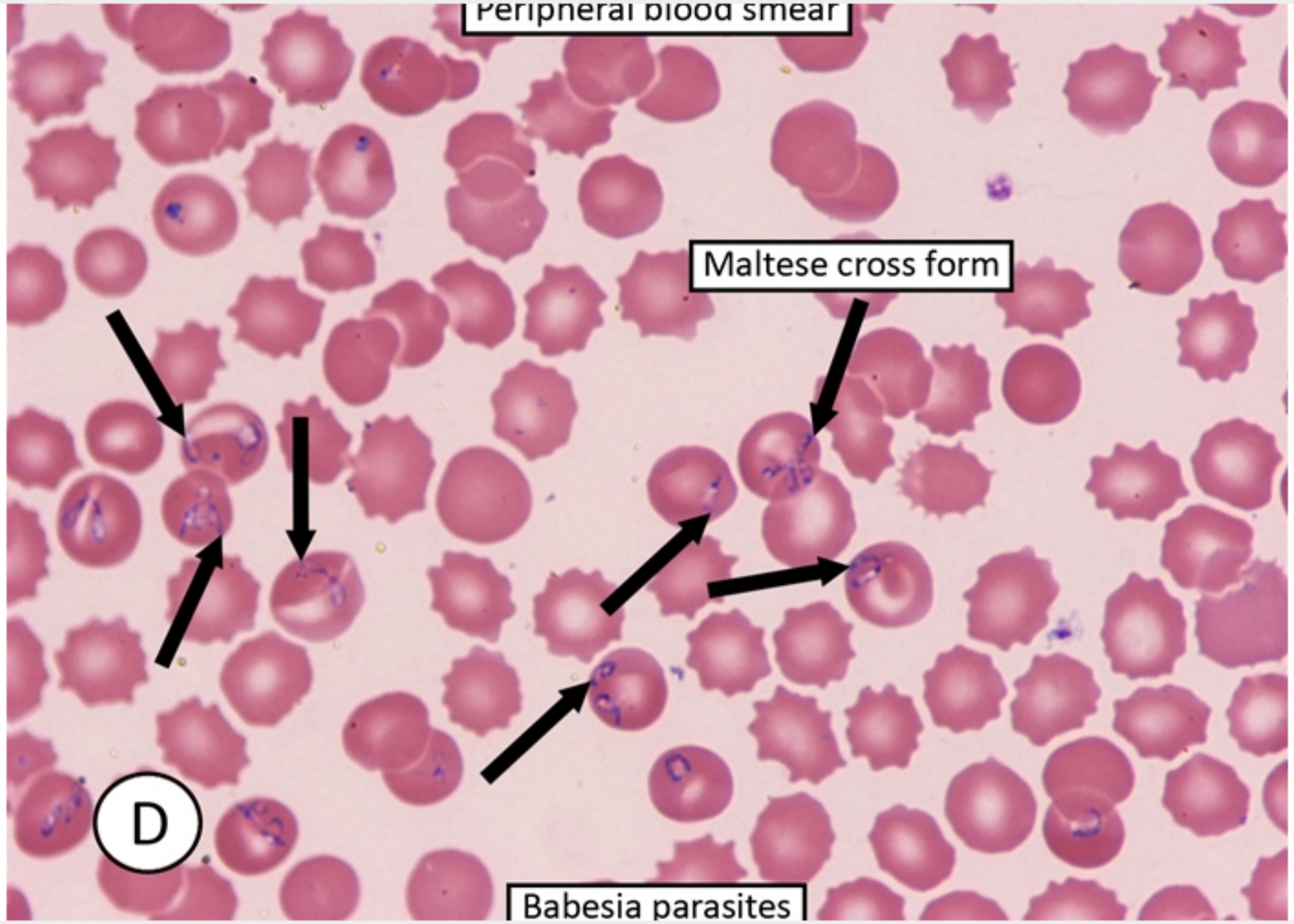

Zoom In Zoom Out Reset Add To New Card | Existing Card

(Choice A) *Aedes* is the vector for dengue fever and chikungunya, which have been diagnosed in Florida but have different presentations (eg, rash, arthralgias) and a short incubation period (<14 days). Malaria is transmitted by *Anopheles* and is endemic in Thailand; although it can also cause intraerythrocytic ring inclusions, it has a typical incubation period of weeks (this patient visited Thailand years ago).

(Choice B) Brown recluse spider bites can cause fever and malaise and less commonly anemia; however, they would not be associated with intraerythrocytic organisms.

(Choice C) Dog bites can be associated with a variety of organisms causing soft-tissue infection, including *Pasteurella*, streptococci, and staphylococci.

(Choice D) Freshwater consumption can be associated with intraintestinal bacterial and parasitic infections such as cryptosporidiosis and giardiasis. However, these infections typically cause gastrointestinal illnesses.

(Choice F) Exposure to plants and soil can be associated with bacterial infections, including *Nocardia* and fungal infections such as sporotrichosis. These most commonly present as soft-tissue infections; systemic infections are rare in immunocompetent patients.

(Choice G) Fungal spore inhalation can lead to pulmonary infections, including histoplasmosis and blastomycosis. These organisms are not endemic to the northeastern United States and are not associated with intraerythrocytic organisms.

Educational objective:
Babesiosis should be considered in patients with febrile illness who reside in geographic areas where they are exposed to *Ixodes* ticks. Diagnosis can be established with the identification of intraerythrocytic organisms on peripheral blood smear.

References

- Babesiosis.
- Human babesiosis.

Microbiology	Infectious Diseases	Babesiosis
Subject	System	Topic

Copyright © UWorld. All rights reserved.

1
2
3
4
5
6
7
8
9
10
11
12
13
14
15
16
17
18
19
20
21
22
23
24
25
26
27
28
29
30
31

A 9-year-old boy is brought to the office due to throat pain and rash. Two days ago, the patient was sent home early from summer camp because of fever, sore throat, pain with eating, and rash on his extremities. He has no prior medical conditions and is up to date on immunizations. Temperature is 37.2 C (99 F); vital signs are otherwise normal. On physical examination, the conjunctivae are normal, and the tympanic membranes are clear. Several superficial ulcers are present on the buccal mucosa and soft palate; the tonsils appear normal and do not have exudate. Skin examination findings are shown in the exhibit. The infectious agent most likely responsible for this patient's current condition is also associated with which of the following?

A. Facial nerve palsy

B. Keratitis

C. Myocarditis

D. Symmetric polyarthritis

E. Temporal lobe encephalitis

Submit

1
2
3
4
5
6
7
8
9
10
11
12
13
14
15
16
17
18
19
20
21
22
23
24
25
26
27
28
29
30
31

Exhibit Display

Zoom In | Zoom Out | Reset | Add To New Card | Existing Card

A 9-year-old boy is brought to the office due to throat pain and rash. Two days ago, the patient was sent home early from summer camp because of fever, sore throat, pain with eating, and rash on his extremities. He has no prior medical conditions and is up to date on immunizations. Temperature is 37.2 C (99 F); vital signs are otherwise normal. On physical examination, the conjunctivae are normal, and the tympanic membranes are clear. Several superficial ulcers are present on the buccal mucosa and soft palate; the tonsils appear normal and do not have exudate. Skin examination findings are shown in the exhibit. The infectious agent most likely responsible for this patient's current condition is also associated with which of the following?

- A. Facial nerve palsy (6%)
- B. Keratitis (6%)
- ✓ C. Myocarditis (55%)
- D. Symmetric polyarthritis (11%)
- E. Temporal lobe encephalitis (19%)

Omitted
Correct answer
C

55%
Answered correctly

09 secs
Time Spent

02/13/2020
Last Updated

Explanation

Enterovirus	
Epidemiology	• Infants & young children • Summer season

Enterovirus	
Epidemiology	• Infants & young children • Summer season • Fecal-oral transmission
Clinical features	• Herpangina (oral ulcerations) • Hand-foot-and-mouth disease (oral & extremity ulcerations) • Aseptic meningitis • Myocarditis

This patient has mouth ulcers and vesicular lesions on his hands, raising strong suspicion for **hand-foot-and-mouth disease** (HFMD). HFMD is caused by several different species of ***Enterovirus*** (*Picornaviridae* family), most often coxsackievirus A or Human enterovirus A. Most cases are transmitted by the fecal-oral route, and **outbreaks** often occur in communal settings (eg, day care, summer camp, schools) during the summer or early autumn; **children** age <7 are primarily affected.

The 2 most common presentations of enterovirus infection are:

- **HFMD**, which is marked by low-grade fever, **oral enanthem** (vesicles/ulcers) on the tongue and buccal mucosa, and macular/**vesicular exanthem** on the **hands**, **feet**, buttocks, legs, and/or arms
- herpangina, which is characterized by high fever, oral ulcers, and no skin findings

Patients with enterovirus infection usually have self-limited disease. However, significant viremia occurs prior to the development of protective antibodies. Although generally asymptomatic and not associated with morbidity, a small minority of patients develop serious **myocarditis** (eg, congestive heart failure) or **CNS disease** (eg, aseptic meningitis).

(Choice A) Facial nerve palsy (Bell palsy) is associated with Lyme disease, which usually presents with a classic bull's-eye rash (erythema migrans) rather than ulcerative enanthem/exanthem.

1 2 3 4 5 6 7 8 9 10 11 12 13 14 15 16 17 18 19 20 21 22 23 24 25 26 27 28 29 30 31

This patient has mouth ulcers and vesicular lesions on his hands, raising strong suspicion for **hand-foot-and-mouth disease** (HFMD). HFMD is caused by several different species of ***Enterovirus*** (*Picornaviridae* family), most often coxsackievirus A or Human enterovirus A. Most cases are transmitted by the fecal-oral route, and **outbreaks** often occur in communal settings (eg, day care, summer camp, schools) during the summer or early autumn; **children** age <7 are primarily affected.

The 2 most common presentations of enterovirus infection are:

- **HFMD**, which is marked by low-grade fever, **oral enanthem** (vesicles/ulcers) on the tongue and buccal mucosa, and macular/**vesicular exanthem** on the **hands**, **feet**, buttocks, legs, and/or arms
- herpangina, which is characterized by high fever, oral ulcers, and no skin findings

Patients with enterovirus infection usually have self-limited disease. However, significant viremia occurs prior to the development of protective antibodies. Although generally asymptomatic and not associated with morbidity, a small minority of patients develop serious **myocarditis** (eg, congestive heart failure) or **CNS disease** (eg, aseptic meningitis).

(Choice A) Facial nerve palsy (Bell palsy) is associated with Lyme disease, which usually presents with a classic bull's-eye rash (erythema migrans) rather than ulcerative enanthem/exanthem.

(Choices B and E) Keratitis (cornea infection) and temporal lobe encephalitis are serious complications of herpes simplex virus (HSV). HSV gingivostomatitis presents with vesicles on the anterior oral mucosa, particularly the lips. Patients may also have concomitant herpetic whitlow, which usually appears as clusters of vesicles on the fingers (not diffuse blisters on the palm). *Enterovirus* is not associated with keratitis, and although it can cause CNS infection, temporal lobe encephalitis is more specific for HSV.

(Choice D) Parvovirus B19 infection can cause a classic "slapped-cheek" rash (fifth disease) or a diffuse, reticulated rash. In some cases, particularly in adolescent girls or adult women, the infection is followed 1-2 weeks later by polyarthralgia or polyarthritis. *Enterovirus* does not usually cause joint manifestations.

Educational objective:
Hand-foot-and-mouth disease (oral ulceration and extremity rash) and herpangina (oral ulcerations without rash) are the most common manifestations of enteroviral infection. Rare but serious complications of infection include myocarditis and central nervous system disease (eg, aseptic meningitis).

1
2
3
4
5
6
7
8
9
10
11
12
13
14
15
16
17
18
19
20
21
22
23
24
25
26
27
28
29
30
31

Patients with enterovirus infection usually have self-limited disease. However, significant viremia occurs prior to the development of protective antibodies. Although generally asymptomatic and not associated with morbidity, a small minority of patients develop serious **myocarditis** (eg, congestive heart failure) or **CNS disease** (eg, aseptic meningitis).

(Choice A) Facial nerve palsy (Bell palsy) is associated with Lyme disease, which usually presents with a classic bull's-eye rash (erythema migrans) rather than ulcerative enanthem/exanthem.

(Choices B and E) Keratitis (cornea infection) and temporal lobe encephalitis are serious complications of herpes simplex virus (HSV). HSV gingivostomatitis presents with vesicles on the anterior oral mucosa, particularly the lips. Patients may also have concomitant herpetic whitlow, which usually appears as clusters of vesicles on the fingers (not diffuse blisters on the palm). *Enterovirus* is not associated with keratitis, and although it can cause CNS infection, temporal lobe encephalitis is more specific for HSV.

(Choice D) Parvovirus B19 infection can cause a classic "slapped-cheek" rash (fifth disease) or a diffuse, reticulated rash. In some cases, particularly in adolescent girls or adult women, the infection is followed 1-2 weeks later by polyarthralgia or polyarthritis. *Enterovirus* does not usually cause joint manifestations.

Educational objective:
Hand-foot-and-mouth disease (oral ulceration and extremity rash) and herpangina (oral ulcerations without rash) are the most common manifestations of enteroviral infection. Rare but serious complications of infection include myocarditis and central nervous system disease (eg, aseptic meningitis).

References

- Tissue tropism, pathology and pathogenesis of enterovirus infection.
- The seasonality of nonpolio enteroviruses in the United States: patterns and drivers.

Microbiology	Infectious Diseases	Hand, foot, mouth disease
Subject	System	Topic

Copyright © UWorld. All rights reserved.

- Myocarditis

Exhibit Display

Zoom In | Zoom Out | Reset | Add To New Card | Existing Card

manifestations of enteroviral infection. Rare but serious complications of infection include myocarditis and central nervous system disease (eg,

- Myocarditis

Exhibit Display

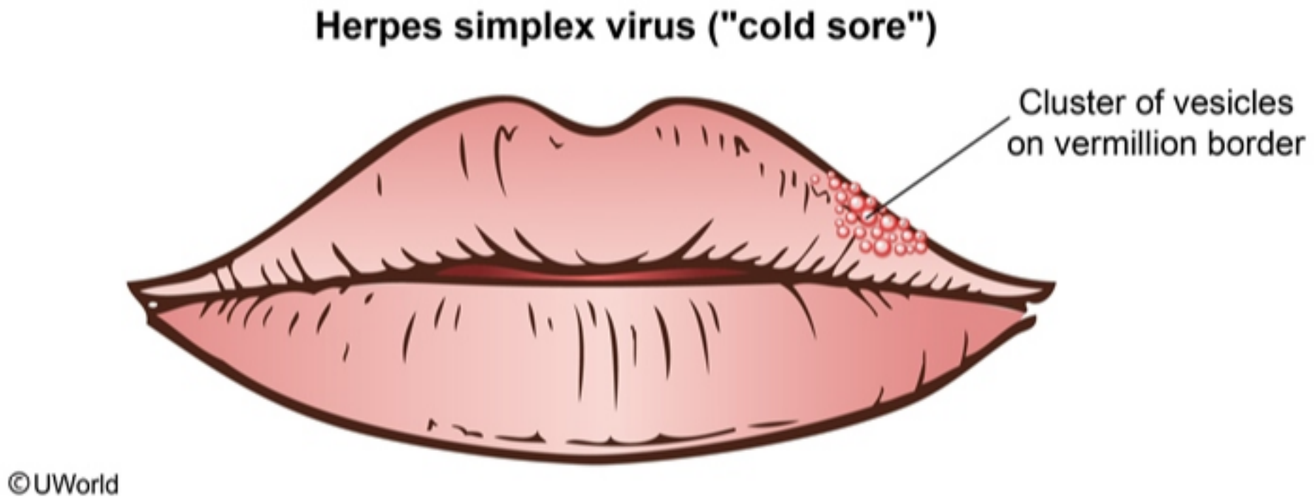

Zoom In | Zoom Out | Reset | Add To New Card | Existing Card

manifestations of enteroviral infection. Rare but serious complications of infection include myocarditis and central nervous system disease (eg,

- Myocarditis

Exhibit Display

Zoom In | Zoom Out | Reset | Add To New Card | Existing Card

manifestations of enteroviral infection. Rare but serious complications of infection include myocarditis and central nervous system disease (eg,

1
2
3
4
5
6
7
8
9
10
11
12
13
14
15
16
17
18
19
20
21
22
23
24
25
26
27
28
29
30
31

Patients with enterovirus infection usually have self-limited disease. However, significant viremia occurs prior to the development of protective antibodies. Although generally asymptomatic and not associated with morbidity, a small minority of patients develop serious **myocarditis** (eg, congestive heart failure) or **CNS disease** (eg, aseptic meningitis).

(Choice A) Facial nerve palsy (Bell palsy) is associated with Lyme disease, which usually presents with a classic bull's-eye rash (erythema migrans) rather than ulcerative enanthem/exanthem.

(Choices B and E) Keratitis (cornea infection) and temporal lobe encephalitis are serious complications of herpes simplex virus (HSV). HSV gingivostomatitis presents with vesicles on the anterior oral mucosa, particularly the lips. Patients may also have concomitant herpetic whitlow, which usually appears as clusters of vesicles on the fingers (not diffuse blisters on the palm). *Enterovirus* is not associated with keratitis, and although it can cause CNS infection, temporal lobe encephalitis is more specific for HSV.

(Choice D) Parvovirus B19 infection can cause a classic "slapped-cheek" rash (fifth disease) or a diffuse, reticulated rash. In some cases, particularly in adolescent girls or adult women, the infection is followed 1-2 weeks later by polyarthralgia or polyarthritis. *Enterovirus* does not usually cause joint manifestations.

Educational objective:
Hand-foot-and-mouth disease (oral ulceration and extremity rash) and herpangina (oral ulcerations without rash) are the most common manifestations of enteroviral infection. Rare but serious complications of infection include myocarditis and central nervous system disease (eg, aseptic meningitis).

References

- Tissue tropism, pathology and pathogenesis of enterovirus infection.
- The seasonality of nonpolio enteroviruses in the United States: patterns and drivers.

Microbiology	Infectious Diseases	Hand, foot, mouth disease
Subject	System	Topic

Copyright © UWorld. All rights reserved.

1
2
3
4
5
6
7
8
9
10
11
12
13
14
15
16
17
18
19
20
21
22
23
24
25
26
27
28
29
30
31

A 5-year-old girl is brought to the office by her mother due to 2 weeks of anorexia, nausea, epigastric discomfort, and loose bowel movements. She has had no fever or bloody stools. The patient recently returned from rural Brazil, where she spent the summer with family. She had no gastrointestinal symptoms during the trip but developed intensely pruritic eruptions between the toes of her right foot. The skin rash spontaneously resolved within a few days and was attributed to insect bites from walking barefoot in the fields. The patient has no prior medical conditions, takes no medications, and has received all age-appropriate vaccinations. On physical examination, the abdomen is soft and nontender with normoactive bowel sounds. Stool microscopy reveals smooth, thin-walled eggs. If left untreated, this patient's condition can lead to which of the following complications?

A. Chronic lymphedema
B. Dilated cardiomyopathy
C. Granulomatous endophthalmitis
D. Microcytic anemia
E. Vitamin B12 deficiency

Submit

1
2
3
4
5
6
7
8
9
10
11
12
13
14
15
16
17
18
19
20
21
22
23
24
25
26
27
28
29
30
31

A 5-year-old girl is brought to the office by her mother due to 2 weeks of anorexia, nausea, epigastric discomfort, and loose bowel movements. She has had no fever or bloody stools. The patient recently returned from rural Brazil, where she spent the summer with family. She had no gastrointestinal symptoms during the trip but developed intensely pruritic eruptions between the toes of her right foot. The skin rash spontaneously resolved within a few days and was attributed to insect bites from walking barefoot in the fields. The patient has no prior medical conditions, takes no medications, and has received all age-appropriate vaccinations. On physical examination, the abdomen is soft and nontender with normoactive bowel sounds. Stool microscopy reveals smooth, thin-walled eggs. If left untreated, this patient's condition can lead to which of the following complications?

A. Chronic lymphedema (8%)

B. Dilated cardiomyopathy (11%)

C. Granulomatous endophthalmitis (5%)

✓ D. Microcytic anemia (53%)

E. Vitamin B12 deficiency (20%)

Omitted
Correct answer
D

53%
Answered correctly

02 secs
Time Spent

02/19/2020
Last Updated

Explanation

Human hookworm life cycle

1
2
3
4
5
6
7
8
9
10
11
12
13
14
15
16
17
18
19
20
21
22
23
24
25
26
27
28
29
30
31

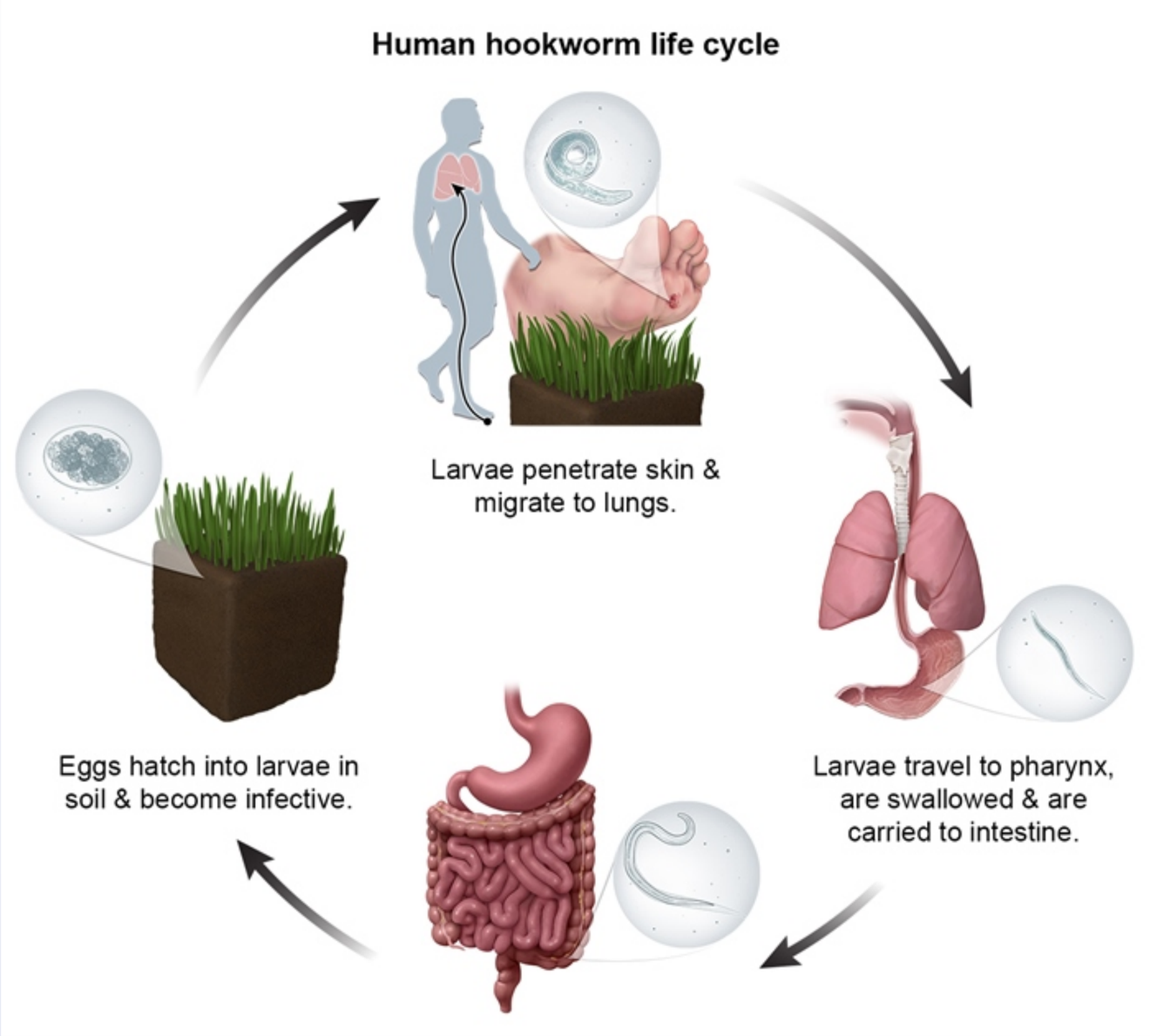

1
2
3
4
5
6
7
8
9
10
11
12
13
14
15
16
17
18
19
20
21
22
23
24
25
26
27
28
29
30
31

In intestine, larvae mature to adult worm. Eggs are passed in stool.

©UWorld

Human hookworm infection is caused by *Necator americanus* and *Ancylostoma duodenale*. These pathogens are called hookworms because the head of the worm is often curved away from the body, giving the organism a "hooked" appearance. Most cases occur in **tropical and subtropical** regions where sanitation is poor. Transmission occurs when **egg-containing human feces** is deposited into shady, warm, moist soil, which allows the eggs to hatch into larvae. Spread occurs when larvae come into direct **contact with human skin** (eg, when walking barefoot).

Dermal penetration often results in a transient, pruritic, maculopapular or serpiginous rash at the entry site. The larvae then spread through the bloodstream to the lungs, where they rupture into the alveoli and are subsequently coughed up and swallowed. In the small intestine, the larvae mature into adults, attach to the gastrointestinal mucosa, and feed on human blood by lacerating capillaries. Because these organisms can live in the gastrointestinal tract for up to 14 years, total blood loss can be substantial. Therefore, the biggest risk of hookworm infection is iron-deficiency anemia **(microcytic anemia)** due to chronic blood loss.

Although many patients with hookworm infection are asymptomatic for months or years, some individuals develop transient pulmonary symptoms (eg, cough) during pulmonary migration or gastrointestinal symptoms (eg, nausea, vomiting, diarrhea) during gastrointestinal migration. Diagnosis is generally made when smooth, thin-walled hookworm eggs are identified by stool microscopy. Peripheral **eosinophilia** is also an important diagnostic clue.

(Choice A) Lymphatic filariasis is a mosquito-borne illness caused by roundworms (eg, *Wuchereria bancrofti*). Most patients are infected in childhood and remain asymptomatic, but a minority develops chronic lymphedema, which may result in elephantiasis. Eggs are not present in stool; diagnosis is made by serology or by identifying worms in the lymphatic system.

(Choice B) Chagas disease is linked to dilated cardiomyopathy and is most common in Latin America. It is caused by the protozoa *Trypanosoma cruzi*. Transmission occurs during a triatomine bug bite. Although transient skin and gastrointestinal symptoms can occur during acute infection, eggs are not seen in the stool; diagnosis is made mostly by serology or by blood microscopy.

(Choice C) Toxocariasis is caused by infection with dog or cat roundworms. Migrating larva cause a significant eosinophilic granulomatous response that can result in ocular (endophthalmitis) and organ damage. Diagnosis is made by serology; the organism does not shed eggs in the gastrointestinal tract.

anemia **(microcytic anemia)** due to chronic blood loss.

Although many patients with hookworm infection are asymptomatic for months or years, some individuals develop transient pulmonary symptoms (eg, cough) during pulmonary migration or gastrointestinal symptoms (eg, nausea, vomiting, diarrhea) during gastrointestinal migration. Diagnosis is generally made when smooth, thin-walled hookworm eggs are identified by stool microscopy. Peripheral **eosinophilia** is also an important diagnostic clue.

(Choice A) Lymphatic filariasis is a mosquito-borne illness caused by roundworms (eg, *Wuchereria bancrofti*). Most patients are infected in childhood and remain asymptomatic, but a minority develops chronic lymphedema, which may result in elephantiasis. Eggs are not present in stool; diagnosis is made by serology or by identifying worms in the lymphatic system.

(Choice B) Chagas disease is linked to dilated cardiomyopathy and is most common in Latin America. It is caused by the protozoa *Trypanosoma cruzi*. Transmission occurs during a triatomine bug bite. Although transient skin and gastrointestinal symptoms can occur during acute infection, eggs are not seen in the stool; diagnosis is made mostly by serology or by blood microscopy.

(Choice C) Toxocariasis is caused by infection with dog or cat roundworms. Migrating larva cause a significant eosinophilic granulomatous response that can result in ocular (endophthalmitis) and organ damage. Diagnosis is made by serology; the organism does not shed eggs in the gastrointestinal tract.

(Choice E) Diphyllobothriasis is caused by infection with a fish tapeworm and is classically linked with megaloblastic anemia due to vitamin B12 deficiency. Although the eggs can be seen on stool microscopy, they are distinguished by a lid-like opening (operculum). In addition, a transient skin rash would not be a feature of this disease.

Educational objective:
Hookworms are transmitted when human skin comes into contact with soil contaminated with human feces. The larvae penetrate the skin, travel to the lungs, are coughed up, and then subsequently swallowed. Adult hookworms live in the small intestine and feed on human blood. Therefore, chronic iron deficiency anemia (microcytic anemia) is the greatest complication.

References

- Soil-transmitted helminth infections.

Microbiology Infectious Diseases Intestinal helminth parasites

anemia **(microcytic anemia)** due to chronic blood loss.

Exhibit Display

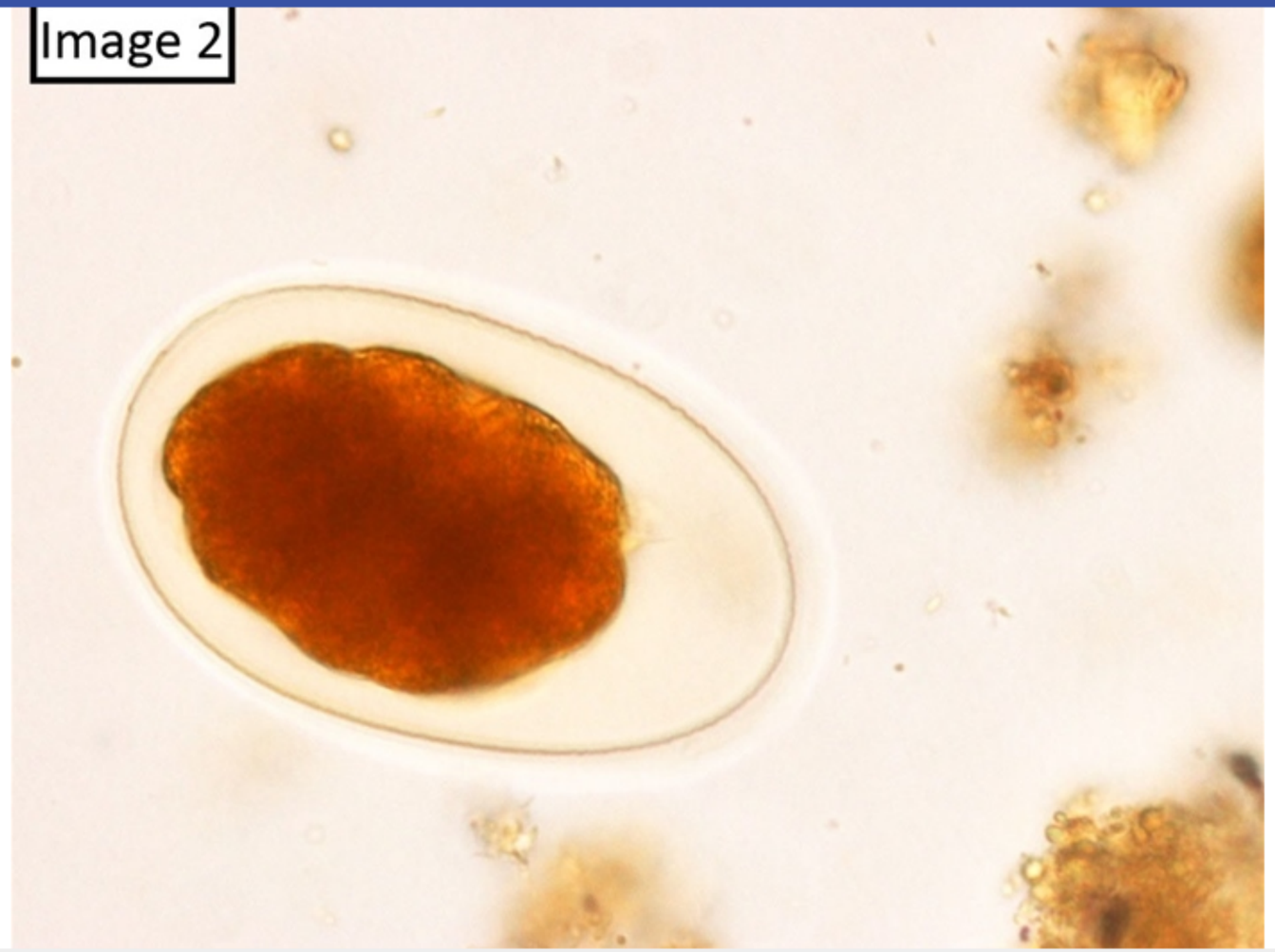

Zoom In | Zoom Out | Reset | Add To New Card | Existing Card

Microbiology | Infectious Diseases | Intestinal helminth parasites

1
2
3
4
5
6
7
8
9
10
11
12
13
14
15
16
17
18
19
20
21
22
23
24
25
26
27
28
29
30
31

1
2
3
4
5
6
7
8
9
10
11
12
13
14
15
16
17
18
19
20
21
22
23
24
25
26
27
28
29
30
31

A 1-month-old boy is brought to the emergency department during winter with cough and difficulty breathing. He has had rhinorrhea, cough, and congestion for the past 3 days. Today, the patient began breathing harder and faster with increased cough. Temperature is 37.8 C (100 F) and respirations are 68/min. Oxygen saturation is 91%. The patient is alert and awake and has subcostal and suprasternal retractions. Mucous membranes are moist, and the anterior fontanelle is open and flat. Physical examination reveals diffuse expiratory wheezes and scattered rales. Which of the following pathogens is most likely causing this patient's condition?

A. Adenovirus

B. *Bordetella pertussis*

C. *Mycoplasma pneumoniae*

D. Parainfluenza virus

E. Respiratory syncytial virus

F. *Streptococcus pneumoniae*

Submit

1
2
3
4
5
6
7
8
9
10
11
12
13
14
15
16
17
18
19
20
21
22
23
24
25
26
27
28
29
30
31

A 1-month-old boy is brought to the emergency department during winter with cough and difficulty breathing. He has had rhinorrhea, cough, and congestion for the past 3 days. Today, the patient began breathing harder and faster with increased cough. Temperature is 37.8 C (100 F) and respirations are 68/min. Oxygen saturation is 91%. The patient is alert and awake and has subcostal and suprasternal retractions. Mucous membranes are moist, and the anterior fontanelle is open and flat. Physical examination reveals diffuse expiratory wheezes and scattered rales. Which of the following pathogens is most likely causing this patient's condition?

- A. Adenovirus (1%)
- B. *Bordetella pertussis* (5%)
- C. *Mycoplasma pneumoniae* (0%)
- D. Parainfluenza virus (6%)
- ✓ E. Respiratory syncytial virus (85%)
- F. *Streptococcus pneumoniae* (1%)

Omitted
Correct answer
E

85%
Answered correctly

02 secs
Time Spent

05/27/2020
Last Updated

Explanation

Bronchiolitis	
Epidemiology	• Age <2 years • RSV most common cause

1
2
3
4
5
6
7
8
9
10
11
12
13
14
15
16
17
18
19
20
21
22
23
24
25
26
27
28
29
30
31

Bronchiolitis	
Epidemiology	• Age <2 years • RSV most common cause
Clinical presentation	• Antecedent nasal congestion/discharge & cough • Wheezing/crackles & respiratory distress (eg, tachypnea, retractions, nasal flaring) • Apnea in high-risk patients
Treatment	• Supportive care

RSV = respiratory syncytial virus.

This infant with worsening cough and respiratory distress has diffuse wheezing and crackles, findings suggestive of **bronchiolitis**. Bronchiolitis is a lower respiratory tract infection that typically affects children age <2 years, usually during the fall and winter. The most common cause is **respiratory syncytial virus** (RSV).

Initial symptoms include rhinorrhea and congestion, followed by cough, low-grade fever, and increased work of breathing. Classic findings include hypoxemia, **tachypnea**, and **retractions** with diffuse **wheezes** and **crackles**. Although illness severity typically peaks at 3-5 days, cough may last several weeks.

In older infants and young children, bronchiolitis is typically a mild, self-limited illness. However, in premature or young (age <2 months) infants, symptoms may be severe (eg, cyanosis, poor perfusion, poor feeding) and lead to apnea and/or respiratory failure.

Diagnosis of bronchiolitis is clinical, and treatment is supportive (eg, supplemental oxygen, nasal suctioning).

(Choices A and D) Adenovirus most commonly causes pharyngitis with conjunctivitis and fever. Parainfluenza virus is the most common cause of croup (laryngotracheobronchitis), which presents with a barky, seal-like cough and inspiratory stridor. Both viruses cause bronchiolitis far less commonly than RSV does.

(Choice B) *Bordetella pertussis* infection in infants classically causes upper respiratory symptoms (eg, rhinorrhea, congestion) with progression to a whooping cough and bouts of coughing and posttussive emesis. In contrast to this patient's examination, the lungs are usually clear to auscultation.

This infant with worsening cough and respiratory distress has diffuse wheezing and crackles, findings suggestive of **bronchiolitis**. Bronchiolitis is a lower respiratory tract infection that typically affects children age <2 years, usually during the fall and winter. The most common cause is **respiratory syncytial virus** (RSV).

Initial symptoms include rhinorrhea and congestion, followed by cough, low-grade fever, and increased work of breathing. Classic findings include hypoxemia, **tachypnea**, and **retractions** with diffuse **wheezes** and **crackles**. Although illness severity typically peaks at 3-5 days, cough may last several weeks.

In older infants and young children, bronchiolitis is typically a mild, self-limited illness. However, in premature or young (age <2 months) infants, symptoms may be severe (eg, cyanosis, poor perfusion, poor feeding) and lead to apnea and/or respiratory failure.

Diagnosis of bronchiolitis is clinical, and treatment is supportive (eg, supplemental oxygen, nasal suctioning).

(Choices A and D) Adenovirus most commonly causes pharyngitis with conjunctivitis and fever. Parainfluenza virus is the most common cause of croup (laryngotracheobronchitis), which presents with a barky, seal-like cough and inspiratory stridor. Both viruses cause bronchiolitis far less commonly than RSV does.

(Choice B) *Bordetella pertussis* infection in infants classically causes upper respiratory symptoms (eg, rhinorrhea, congestion) with progression to a whooping cough and bouts of coughing and posttussive emesis. In contrast to this patient's examination, the lungs are usually clear to auscultation.

(Choice C) Pneumonia caused by *Mycoplasma pneumoniae* typically presents with fever, cough, and rales and wheezing on examination. However, *M pneumoniae* usually affects children age >5 years and is a rare cause of bronchiolitis.

(Choice F) *Streptococcus pneumoniae* is the most common cause of lobar pneumonia in children and presents with fever and cough. However, examination typically reveals focal rales, not diffuse findings, as seen in this patient.

Educational objective:
Viral bronchiolitis is most commonly caused by respiratory syncytial virus and presents with low-grade fever, cough, and respiratory distress (eg, tachypnea, retractions) in children age <2 years. Examination typically shows diffuse wheezes and/or crackles.

References

- Pediatric bronchiolitis

1
2
3
4
5
6
7
8
9
10
11
12
13
14
15
16
17
18
19
20
21
22
23
24
25
26
27
28
29
30
31

several weeks.

In older infants and young children, bronchiolitis is typically a mild, self-limited illness. However, in premature or young (age <2 months) infants, symptoms may be severe (eg, cyanosis, poor perfusion, poor feeding) and lead to apnea and/or respiratory failure.

Diagnosis of bronchiolitis is clinical, and treatment is supportive (eg, supplemental oxygen, nasal suctioning).

(Choices A and D) Adenovirus most commonly causes pharyngitis with conjunctivitis and fever. Parainfluenza virus is the most common cause of croup (laryngotracheobronchitis), which presents with a barky, seal-like cough and inspiratory stridor. Both viruses cause bronchiolitis far less commonly than RSV does.

(Choice B) *Bordetella pertussis* infection in infants classically causes upper respiratory symptoms (eg, rhinorrhea, congestion) with progression to a whooping cough and bouts of coughing and posttussive emesis. In contrast to this patient's examination, the lungs are usually clear to auscultation.

(Choice C) Pneumonia caused by *Mycoplasma pneumoniae* typically presents with fever, cough, and rales and wheezing on examination. However, *M pneumoniae* usually affects children age >5 years and is a rare cause of bronchiolitis.

(Choice F) *Streptococcus pneumoniae* is the most common cause of lobar pneumonia in children and presents with fever and cough. However, examination typically reveals focal rales, not diffuse findings, as seen in this patient.

Educational objective:
Viral bronchiolitis is most commonly caused by respiratory syncytial virus and presents with low-grade fever, cough, and respiratory distress (eg, tachypnea, retractions) in children age <2 years. Examination typically shows diffuse wheezes and/or crackles.

References

- Pediatric bronchiolitis.

Microbiology	Infectious Diseases	Bronchiolitis
Subject	System	Topic

Copyright © UWorld. All rights reserved.

1
2
3
4
5
6
7
8
9
10
11
12
13
14
15
16
17
18
19
20
21
22
23
24
25
26
27
28
29
30
31

A 46-year-old woman comes to the office to be tested for HIV after one of her prior sexual partners found that he was HIV-positive. She feels healthy and has no symptoms. The patient has never had a sexually transmitted infection and has no chronic medical conditions. She has had several sexual partners in her lifetime and uses condoms inconsistently. Physical examination shows no abnormalities. HIV antigen/antibody immunoassay and a confirmatory HIV-1 antibody test are positive. Further studies reveal plasma HIV viral load is >250,000 copies/mL and CD4 lymphocyte count is 150 cells/mm^3. After discussing the results and need for treatment, the patient agrees to start antiretroviral therapy. An additional medication to prevent opportunistic infections is also planned. This added treatment is most likely being used to prevent infection from which of the following pathogens?

A. *Candida albicans*
B. *Cryptococcus neoformans*
C. Cytomegalovirus
D. *Mycobacterium avium-intracellular*
E. *Pneumocystis jirovecii*
F. *Toxoplasma gondii*

Submit

1
2
3
4
5
6
7
8
9
10
11
12
13
14
15
16
17
18
19
20
21
22
23
24
25
26
27
28
29
30
31

A 46-year-old woman comes to the office to be tested for HIV after one of her prior sexual partners found that he was HIV-positive. She feels healthy and has no symptoms. The patient has never had a sexually transmitted infection and has no chronic medical conditions. She has had several sexual partners in her lifetime and uses condoms inconsistently. Physical examination shows no abnormalities. HIV antigen/antibody immunoassay and a confirmatory HIV-1 antibody test are positive. Further studies reveal plasma HIV viral load is >250,000 copies/mL and CD4 lymphocyte count is 150 cells/mm^3. After discussing the results and need for treatment, the patient agrees to start antiretroviral therapy. An additional medication to prevent opportunistic infections is also planned. This added treatment is most likely being used to prevent infection from which of the following pathogens?

A. *Candida albicans* (9%)

B. *Cryptococcus neoformans* (3%)

C. Cytomegalovirus (3%)

D. *Mycobacterium avium-intracellular* (6%)

✓ E. *Pneumocystis jirovecii* (71%)

F. *Toxoplasma gondii* (6%)

Omitted
Correct answer
E

71%
Answered correctly

02 secs
Time Spent

02/23/2020
Last Updated

Explanation

Opportunistic infections in HIV

Opportunistic infections in HIV		
Infection	**Risk factors**	**Prophylaxis**
Pneumocystis jirovecii	• CD4 count <200/mm^3 • Oropharyngeal candidiasis	• Trimethoprim-sulfamethoxazole
Toxoplasma gondii	• CD4 count <100/mm^3 • Positive *Toxoplasma* IgG antibody	• Trimethoprim-sulfamethoxazole
Mycobacterium avium complex (*M avium* & *M intracellulare*)	• CD4 count <50/mm^3	• Azithromycin

Patients with **HIV** have progressive impairment of the cell-mediated immune response that puts them at risk for **opportunistic infections** (OIs) with bacterial, viral, fungal, and protozoal pathogens. OIs are associated with significant morbidity and mortality and also worsen HIV progression and viremia. **Antimicrobial prophylaxis** can decrease the risk of developing certain OIs and is recommended in addition to antiretroviral therapy for all patients with HIV who have CD4 counts **<200/mm^3**.

Antimicrobial prophylaxis is guided by the patient's CD4 count, as follows:

- CD4 count <200/mm^3 – Antimicrobial prophylaxis against ***Pneumocystis jiroveci* pneumonia** is indicated. **Trimethoprim-sulfamethoxazole** is the first-line agent.
- CD4 count <100/mm^3 – Patients require antimicrobial prophylaxis against *Toxoplasma gondii* reactivation if they have serologic evidence of previous exposure (positive *Toxoplasma* IgG antibody). Trimethoprim-sulfamethoxazole is also used for prophylaxis against this condition **(Choice F)**.
- CD4 count <50/mm^3 – Patients require antimicrobial prophylaxis against *Mycobacterium avium-intracellular* (mycobacterium avium complex). Azithromycin is used most commonly **(Choice D)**.

Once CD4 counts improve with antiretroviral therapy (>200/mm^3 for >3 months), patients can often stop taking antimicrobial prophylaxis.

(Choice A) Patients with advanced HIV who have low CD4 counts are at greater risk for mucocutaneous *Candida* infections (eg, thrush,

for all patients with HIV who have CD4 counts **<200/mm³**.

Antimicrobial prophylaxis is guided by the patient's CD4 count, as follows:

- CD4 count <200/mm³ – Antimicrobial prophylaxis against ***Pneumocystis jiroveci* pneumonia** is indicated. **Trimethoprim-sulfamethoxazole** is the first-line agent.
- CD4 count <100/mm³ – Patients require antimicrobial prophylaxis against *Toxoplasma gondii* reactivation if they have serologic evidence of previous exposure (positive *Toxoplasma* IgG antibody). Trimethoprim-sulfamethoxazole is also used for prophylaxis against this condition **(Choice F)**.
- CD4 count <50/mm³ – Patients require antimicrobial prophylaxis against *Mycobacterium avium-intracellular* (mycobacterium avium complex). Azithromycin is used most commonly **(Choice D)**.

Once CD4 counts improve with antiretroviral therapy (>200/mm³ for >3 months), patients can often stop taking antimicrobial prophylaxis.

(Choice A) Patients with advanced HIV who have low CD4 counts are at greater risk for mucocutaneous *Candida* infections (eg, thrush, esophagitis). However, routine prophylaxis against *Candida* infection is not recommended due to risk of drug resistance and drug interactions.

(Choice B) Patients with HIV who have CD4 counts <100/mm³ are at risk for cryptococcal meningitis. However, prophylaxis is not recommended against *Cryptococcus* due to drug interactions, adverse effects, risk of fungal resistance, and cost. This patient's CD4 count >100/mm³.

(Choice C) Cytomegalovirus (CMV) is a common OI in patients with HIV who have CD4 counts <50/mm³. Reactivation frequently leads to retinitis and gastrointestinal disease (eg, colitis). However, primary prophylaxis against CMV is not recommended due to cost, toxicity, and the high number needed to treat to reduce risk of disease.

Educational objective:
Patients with advanced HIV and low CD4 counts are at risk for opportunistic infections and require antimicrobial prophylaxis. *Pneumocystis jiroveci* pneumonia prophylaxis with trimethoprim-sulfamethoxazole (TMP-SMX) is indicated when CD4 count is <200/mm³.

Microbiology	Infectious Diseases	HIV
Subject	System	Topic

1
2
3
4
5
6
7
8
9
10
11
12
13
14
15
16
17
18
19
20
21
22
23
24
25
26
27
28
29
30
31

A 29-year-old man is hospitalized due to a flulike illness. His symptoms abruptly began 3 days ago with fever, rigors, malaise, headache, and myalgia. The patient has no prior health conditions and is usually very active, participating in multiple outdoor sports. Temperature is 38.9 C (102 F), blood pressure is 124/84 mm Hg, and pulse is 110/min. Physical examination shows an ill-appearing man with bilateral conjunctival suffusion. Lung and heart sounds are normal, but abdominal examination reveals mild hepatosplenomegaly. Generalized lymphadenopathy is also present. A test for influenza antigen is negative, and blood cultures in routine growth media are negative. The patient subsequently develops progressive jaundice and renal failure. Further testing detects an infection with a highly motile, corkscrew-shaped pathogen. This patient most likely acquired the infection via which of the following?

- A. Being in close vicinity of infected bats
- B. Bites from infected rodent fleas
- C. Exposure to water contaminated with animal urine
- D. Hiking in tick-infested wooded areas
- E. Hunting and skinning of wild rabbits

Submit

1
2
3
4
5
6
7
8
9
10
11
12
13
14
15
16
17
18
19
20
21
22
23
24
25
26
27
28
29
30
31

A 29-year-old man is hospitalized due to a flulike illness. His symptoms abruptly began 3 days ago with fever, rigors, malaise, headache, and myalgia. The patient has no prior health conditions and is usually very active, participating in multiple outdoor sports. Temperature is 38.9 C (102 F), blood pressure is 124/84 mm Hg, and pulse is 110/min. Physical examination shows an ill-appearing man with bilateral conjunctival suffusion. Lung and heart sounds are normal, but abdominal examination reveals mild hepatosplenomegaly. Generalized lymphadenopathy is also present. A test for influenza antigen is negative, and blood cultures in routine growth media are negative. The patient subsequently develops progressive jaundice and renal failure. Further testing detects an infection with a highly motile, corkscrew-shaped pathogen. This patient most likely acquired the infection via which of the following?

- A. Being in close vicinity of infected bats (2%)
- B. Bites from infected rodent fleas (3%)
- ✓ C. Exposure to water contaminated with animal urine (73%)
- D. Hiking in tick-infested wooded areas (15%)
- E. Hunting and skinning of wild rabbits (4%)

Omitted
Correct answer
C

73%
Answered correctly

03 secs
Time Spent

02/10/2020
Last Updated

Explanation

Leptospirosis is a widespread, zoonotic infection caused by several species of *Leptospira*, a thin, highly coiled, **motile spirochete** that infects wild (eg, rodents) and domestic (eg, dogs, cattle) animals. Infected animals harbor the organism in the proximal renal tubule and excrete it in urine. Transmission to humans primarily occurs during outdoor recreational (eg, kayaking, freshwater swimming) or occupational activities that

1
2
3
4
5
6
7
8
9
10
11
12
13
14
15
16
17
18
19
20
21
22
23
24
25
26
27
28
29
30
31

Leptospirosis is a widespread, zoonotic infection caused by several species of *Leptospira*, a thin, highly coiled, **motile spirochete** that infects wild (eg, rodents) and domestic (eg, dogs, cattle) animals. Infected animals harbor the organism in the proximal renal tubule and excrete it in urine. Transmission to humans primarily occurs during outdoor recreational (eg, kayaking, freshwater swimming) or occupational activities that exposes them to **water contaminated with animal urine**.

Most cases of leptospirosis are mild or subclinical. However, some patients develop a **flu-like illness** (eg, fever, rigors, myalgia, headache), lymphadenopathy, or more severe end-organ disease such as renal failure or hepatic failure (eg, jaundice, hepatomegaly). **Conjunctival suffusion**, redness of the conjunctiva that resembles conjunctivitis but is noninflammatory, is an important diagnostic clue. Because spirochetes do not grow well on traditional culture media, initial testing (eg, influenza antigen, blood culture) is often negative. However, specialized culture media can often identify the **corkscrew-shaped organism**. Most cases are self-limited and do not require treatment.

(Choice A) Bats can transmit rabies to humans via a bite wound. Manifestations typically begin with flulike symptoms and progress to fever, hydrophobia, pharyngeal spasms, coma, and death. Rabies is a cylindrical, enveloped RNA virus; it is not a motile, corkscrew-shaped organism.

(Choice B) *Yersinia*, a bacteria transmitted by animal (eg, rodent) fleas, can cause bubonic plague, which typically presents with sudden-onset, flulike symptoms followed by intense pain and regional lymphadenopathy (eg, inguinal). *Yersinia* grows well on traditional culture media; it appears on Gram stain as a gram-negative coccobacillus.

(Choice D) Rocky Mountain spotted fever is a tickborne illness caused by the small, gram-negative bacterium *Rickettsia rickettsii*. Although initial symptoms are often flulike and may include conjunctivitis, most individuals develop an erythematous rash that begins on the wrists and ankles, spreads to the center of the body, and includes the palms and soles. The organism is not corkscrew-shaped.

(Choice E) Tularemia is caused by the gram-negative bacterium *Francisella tularensis*, which frequently infects rabbits. Manifestations typically include flulike symptoms followed by lymphadenopathy and a papulo-ulcerative eschar at the site of inoculation.

Educational objective:
Leptospirosis is a zoonotic infection caused by the motile spirochete *Leptospira*. Transmission primarily occurs when humans come into contact with water contaminated with animal urine during outdoor recreational or occupational activities. Patients classically have a mild, self-limited, flulike illness but may develop more serious complications such as renal or hepatic failure.

References

- Leptospirosis in humans

lymphadenopathy, or more severe end-organ disease such as renal failure or hepatic failure (eg, jaundice, hepatomegaly). **Conjunctival suffusion**, redness of the conjunctiva that resembles conjunctivitis but is noninflammatory, is an important diagnostic clue. Because spirochetes do not grow well on traditional culture media, initial testing (eg, influenza antigen, blood culture) is often negative. However, specialized culture media can often identify the **corkscrew-shaped organism**. Most cases are self-limited and do not require treatment.

(Choice A) Bats can transmit rabies to humans via a bite wound. Manifestations typically begin with flulike symptoms and progress to fever, hydrophobia, pharyngeal spasms, coma, and death. Rabies is a cylindrical, enveloped RNA virus; it is not a motile, corkscrew-shaped organism.

(Choice B) *Yersinia*, a bacteria transmitted by animal (eg, rodent) fleas, can cause bubonic plague, which typically presents with sudden-onset, flulike symptoms followed by intense pain and regional lymphadenopathy (eg, inguinal). *Yersinia* grows well on traditional culture media; it appears on Gram stain as a gram-negative coccobacillus.

(Choice D) Rocky Mountain spotted fever is a tickborne illness caused by the small, gram-negative bacterium *Rickettsia rickettsii*. Although initial symptoms are often flulike and may include conjunctivitis, most individuals develop an erythematous rash that begins on the wrists and ankles, spreads to the center of the body, and includes the palms and soles. The organism is not corkscrew-shaped.

(Choice E) Tularemia is caused by the gram-negative bacterium *Francisella tularensis*, which frequently infects rabbits. Manifestations typically include flulike symptoms followed by lymphadenopathy and a papulo-ulcerative eschar at the site of inoculation.

Educational objective:
Leptospirosis is a zoonotic infection caused by the motile spirochete *Leptospira*. Transmission primarily occurs when humans come into contact with water contaminated with animal urine during outdoor recreational or occupational activities. Patients classically have a mild, self-limited, flulike illness but may develop more serious complications such as renal or hepatic failure.

References

- Leptospirosis in humans.

Microbiology	Infectious Diseases	Leptospirosis
Subject	System	Topic

Copyright © UWorld. All rights reserved.

1
2
3
4
5
6
7
8
9
10
11
12
13
14
15
16
17
18
19
20
21
22
23
24
25
26
27
28
29
30
31

A 47-year-old man initially comes to his primary care physician with persistent fever, night sweats, and fatigue. Thorough evaluation yields a diagnosis of chronic myeloid leukemia. While undergoing treatment for his malignancy, the patient comes to the oncologist complaining of headaches, scant nasal discharge, and a problem with his left eye. Physical examination reveals tenderness over the paranasal sinuses in addition to left-sided orbital swelling and cellulitis. Mild proptosis and ptosis of the left eye are also present. Biopsy of his sinus mucosa is shown below.

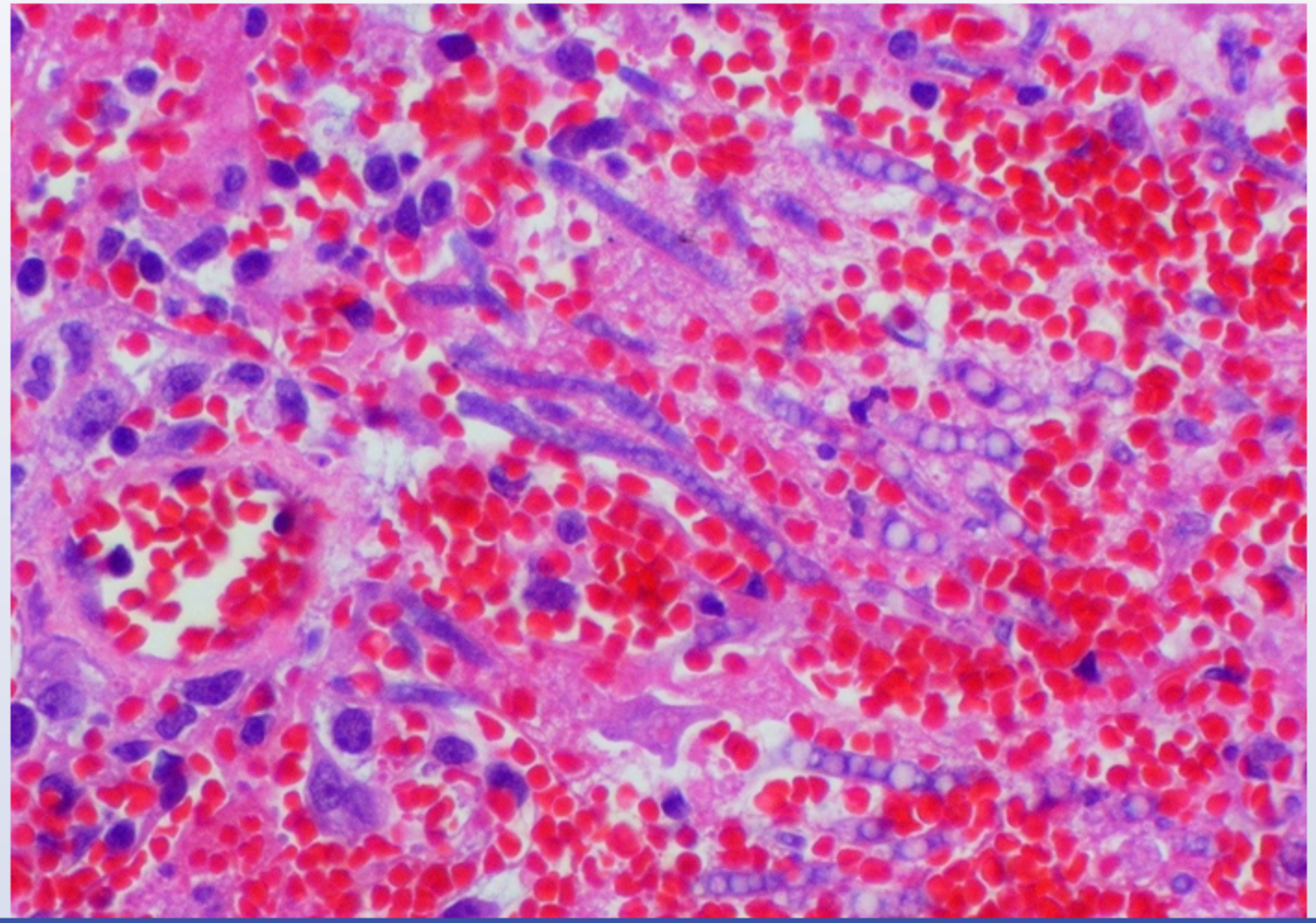

below.

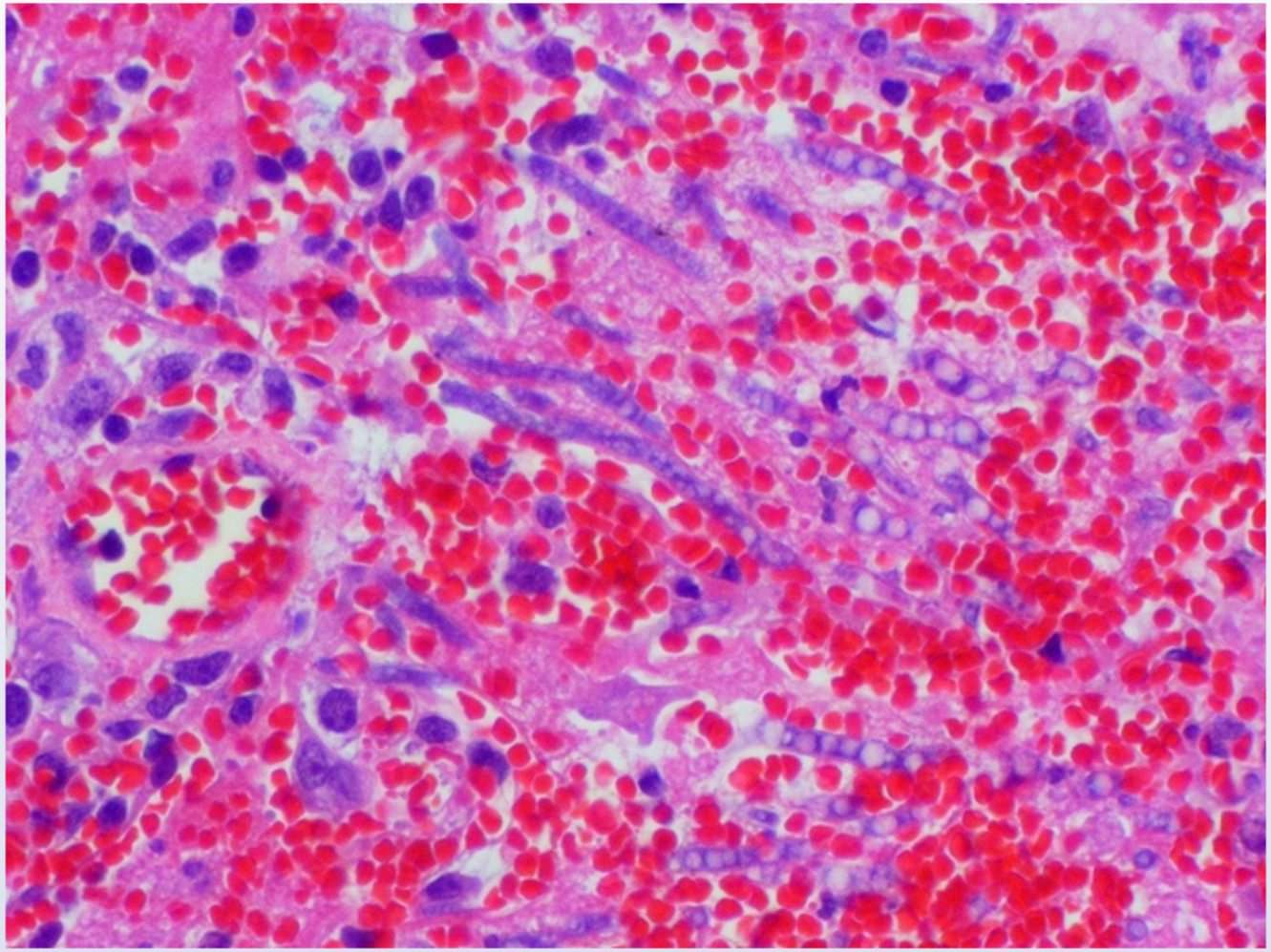

Which of the following is the most likely cause of this patient's condition?

A. *Aspergillus fumigatus*

1
2
3
4
5
6
7
8
9
10
11
12
13
14
15
16
17
18
19
20
21
22
23
24
25
26
27
28
29
30
31

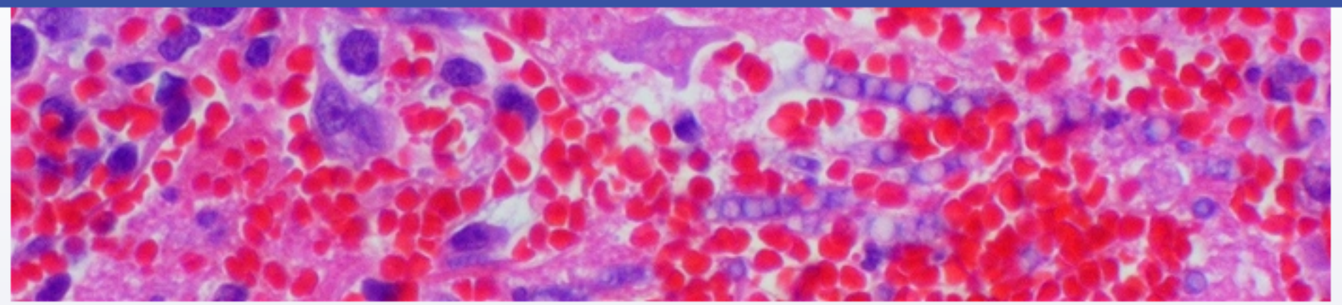

Which of the following is the most likely cause of this patient's condition?

A. *Aspergillus fumigatus*

B. *Blastomyces dermatitidis*

C. *Candida albicans*

D. *Coccidioides immitis*

E. *Cryptococcus neoformans*

F. *Histoplasma capsulatum*

G. *Malassezia furfur*

H. *Microsporum canis*

I. *Rhizopus species*

J. *Sporothrix schenckii*

Submit

1
2
3
4
5
6
7
8
9
10
11
12
13
14
15
16
17
18
19
20
21
22
23
24
25
26
27
28
29
30
31

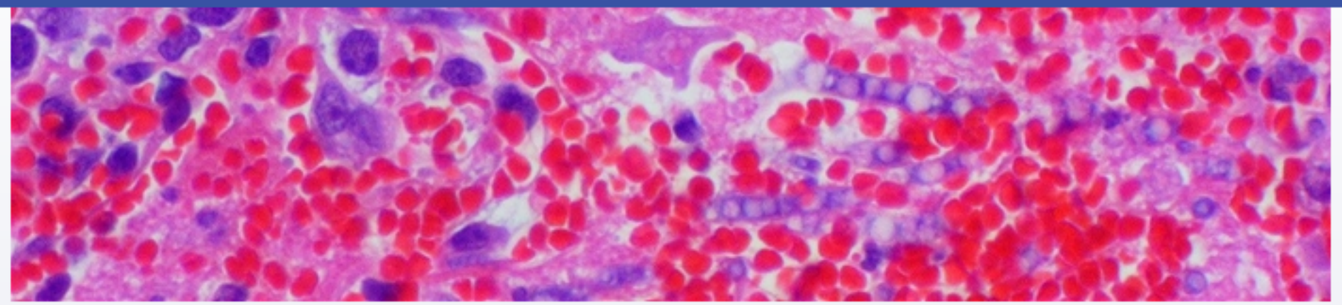

Which of the following is the most likely cause of this patient's condition?

- ✓ A. *Aspergillus fumigatus* (35%)
- B. *Blastomyces dermatitidis* (1%)
- C. *Candida albicans* (4%)
- D. *Coccidioides immitis* (1%)
- E. *Cryptococcus neoformans* (3%)
- F. *Histoplasma capsulatum* (1%)
- G. *Malassezia furfur* (3%)
- H. *Microsporum canis* (0%)
- I. *Rhizopus species* (45%)
- J. *Sporothrix schenckii* (0%)

Omitted
Correct answer

35%
Answered correctly

07 secs
Time Spent

05/22/2020
Last Updated

1
2
3
4
5
6
7
8
9
10
11
12
13
14
15
16
17
18
19
20
21
22
23
24
25
26
27
28
29
30
31

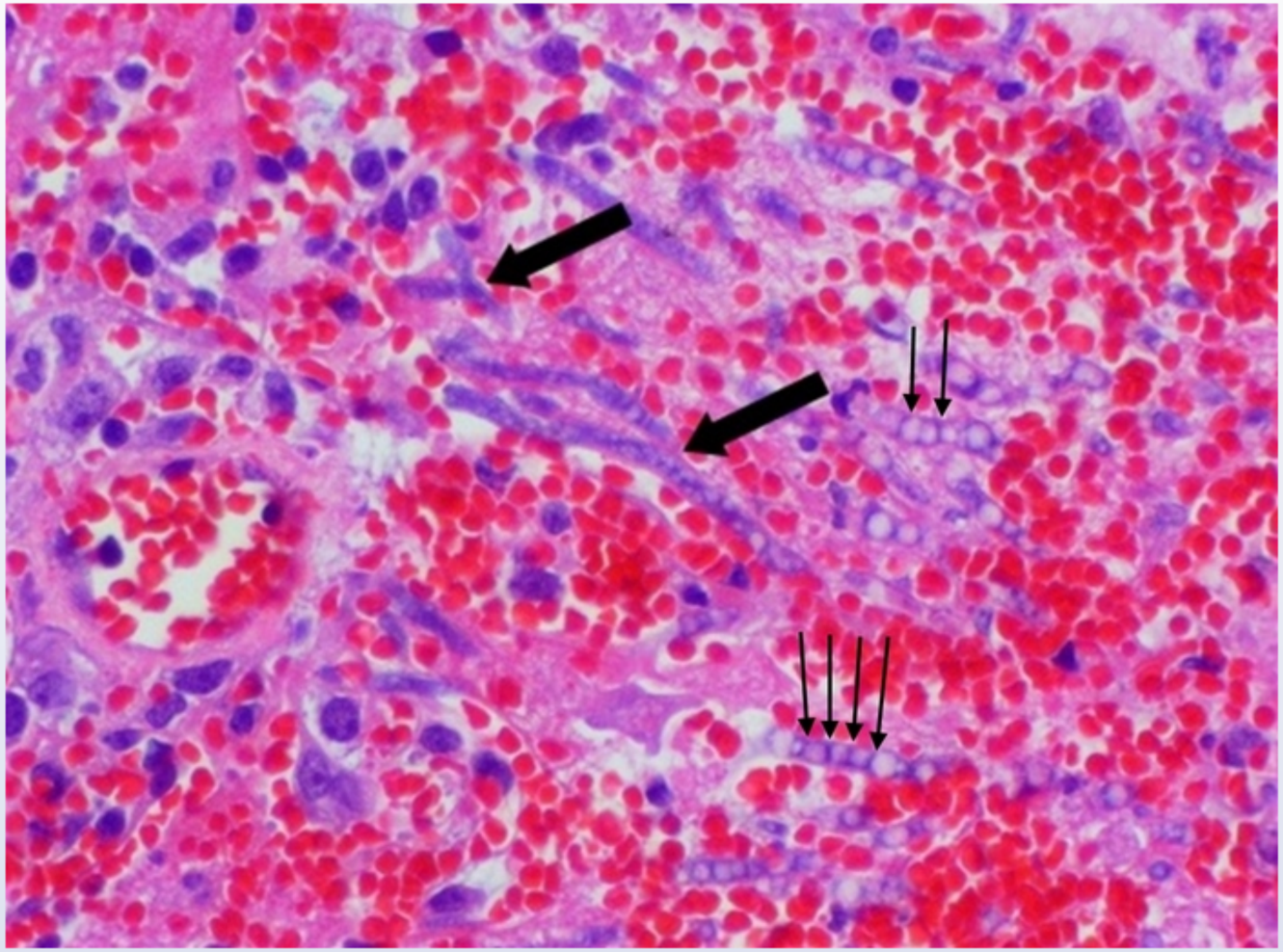

This patient's symptoms are consistent with fungal rhinosinusitis. The biopsy image shows fungal hyphae branching at acute angles (thick arrows) with septations (thin arrows), which is characteristic of *Aspergillus fumigatus*. This fungus is widely distributed in the environment and commonly grows on decaying vegetables. It is monomorphic, existing only in mold form (ie, multicellular hyphae).

1
2
3
4
5
6
7
8
9
10
11
12
13
14
15
16
17
18
19
20
21
22
23
24
25
26
27
28
29
30
31

This patient's symptoms are consistent with fungal rhinosinusitis. The biopsy image shows fungal hyphae branching at acute angles (thick arrows) with septations (thin arrows), which is characteristic of *Aspergillus fumigatus*. This fungus is widely distributed in the environment and commonly grows on decaying vegetables. It is monomorphic, existing only in mold form (ie, multicellular hyphae).

Aspergillus causes the following conditions:

1. **Invasive aspergillosis** develops in **immunosuppressed patients**. The prolonged neutropenia associated with leukemia and lymphoma treatment is a strong risk factor for invasive aspergillosis. It most commonly affects the lung, causing the formation of lung granulomas with development of fever, pleuritic chest pain, and hemoptysis. *Aspergillus* has a predilection for blood vessels and can spread hematogenously, causing infection and infarcts involving the skin, paranasal sinuses, kidneys, endocardium, and brain. Diagnosis is made by light microscopy of tissue specimens, which shows V-shaped, narrow, septate hyphae invading the tissue. Amphotericin B is used to treat invasive aspergillosis.
2. **Aspergillomas** are **fungus balls** caused by *Aspergillus* that grow in old lung cavities (eg, produced by tuberculosis or bronchiectasis). Aspergillomas are limited to the preexisting cavity; invasion of the surrounding lung tissue is rare in immunocompetent patients. They are often surgically removed.
3. **Allergic bronchopulmonary aspergillosis** occurs in patients with asthma and presents with wheezing and have migratory pulmonary infiltrates. Increased serum IgE and increased titers of antibodies against *Aspergillus* are characteristic. Treatment is with corticosteroids.

(Choices B, D and F) *Blastomyces*, *Histoplasma*, and *Coccidioides* are dimorphic fungi. They grow as molds in nature but exist in the human body in yeast form (*Coccidioides* exists in endospore form at body temperature). As a result, hyphae would not be seen in biopsy specimens.

(Choice C) *Candida albicans* is a component of normal human mucous membrane flora. On light microscopy, it appears as an oval budding yeast with pseudohyphae (ie, not true hyphae but rather elongated yeast cells).

(Choice E) *Cryptococcus neoformans* causes meningitis and lung infections in patients with AIDS. It is an oval budding yeast with a thick capsule. India ink stain of the cerebrospinal fluid shows a wide clear zone around the cell corresponding to the unstained capsule.

(Choice I) ***Rhizopus*** and *Mucor* form broad, ribbon-shaped, **non-septate** hyphae that branch at **wide angles**. They cause mucormycosis, which typically presents as a paranasal infection in immunocompromised patients or those with diabetes mellitus. However, *Aspergillus* can also cause rhinosinusitis identical in presentation to mucormycosis. The presence of narrow hyphae with septations makes invasive aspergillosis a better diagnosis.

often surgically removed.

3. **Allergic bronchopulmonary aspergillosis** occurs in patients with asthma and presents with wheezing and have migratory pulmonary infiltrates. Increased serum IgE and increased titers of antibodies against *Aspergillus* are characteristic. Treatment is with corticosteroids.

(Choices B, D and F) *Blastomyces*, *Histoplasma*, and *Coccidioides* are dimorphic fungi. They grow as molds in nature but exist in the human body in yeast form (*Coccidioides* exists in endospore form at body temperature). As a result, hyphae would not be seen in biopsy specimens.

(Choice C) *Candida albicans* is a component of normal human mucous membrane flora. On light microscopy, it appears as an oval budding yeast with pseudohyphae (ie, not true hyphae but rather elongated yeast cells).

(Choice E) *Cryptococcus neoformans* causes meningitis and lung infections in patients with AIDS. It is an oval budding yeast with a thick capsule. India ink stain of the cerebrospinal fluid shows a wide clear zone around the cell corresponding to the unstained capsule.

(Choice I) ***Rhizopus*** and *Mucor* form broad, ribbon-shaped, **non-septate** hyphae that branch at **wide angles**. They cause mucormycosis, which typically presents as a paranasal infection in immunocompromised patients or those with diabetes mellitus. However, *Aspergillus* can also cause rhinosinusitis identical in presentation to mucormycosis. The presence of narrow hyphae with septations makes invasive aspergillosis a better diagnosis.

Educational objective:
Immunosuppressed patients are at risk for *Aspergillus fumigatus* infection. This fungus produces thin, septate hyphae with acute V-shaped branching. It causes invasive aspergillosis, aspergillomas, and allergic pulmonary aspergillosis.

References

- Fungal infections in leukemia patients: how do we prevent and treat them?
- Fungal rhinosinusitis: a categorization and definitional schema addressing current controversies.

Microbiology	Infectious Diseases	Aspergillosis
Subject	System	Topic

Copyright © UWorld. All rights reserved.

often surgically removed.

Exhibit Display

Mucormycosis Abdominal Mucormycosis

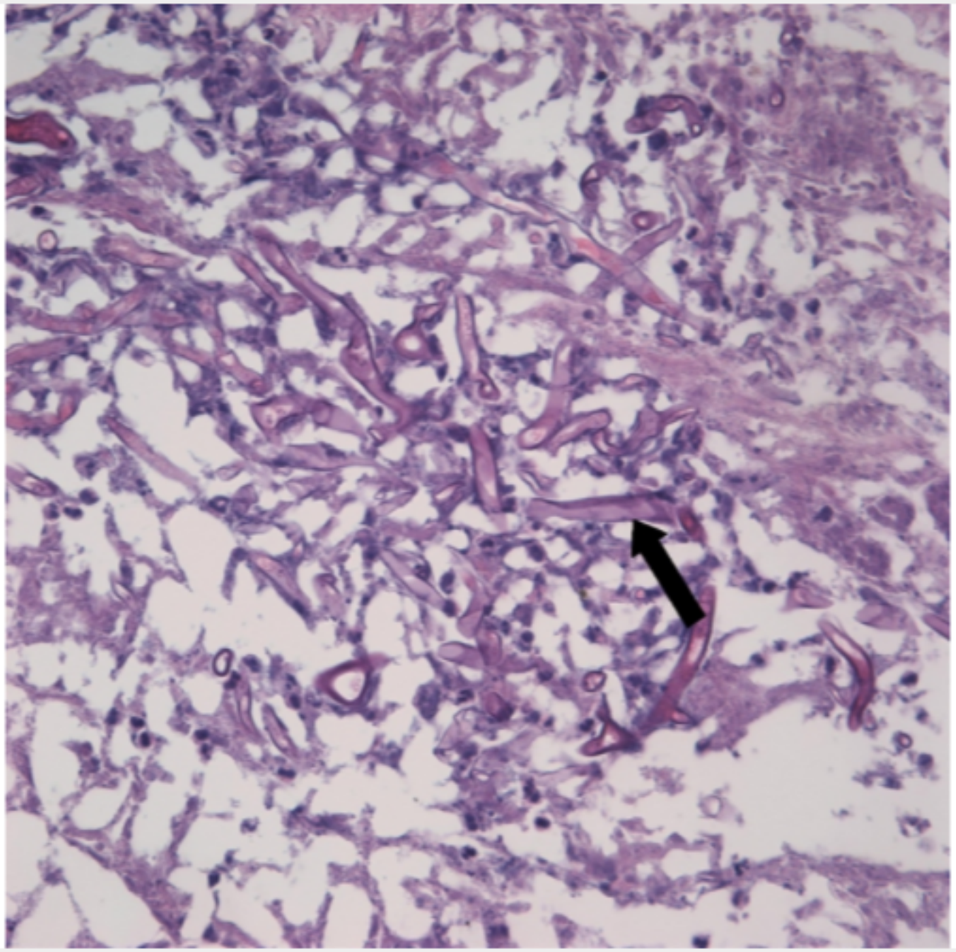

Zoom In Zoom Out Reset Add To New Card | Existing Card

often surgically removed.

Exhibit Display

Mucormycosis Abdominal Mucormycosis

Abdominal mucormycosis

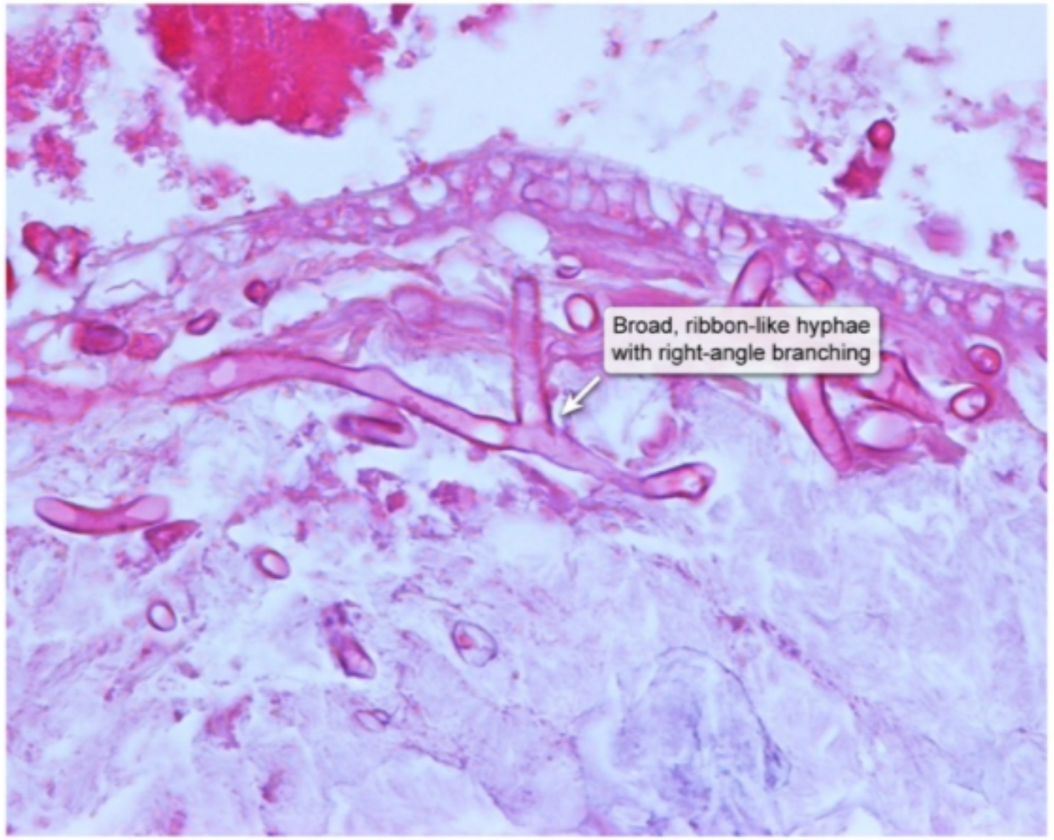

©UWorld

Zoom In Zoom Out Reset Add To New Card | Existing Card

1
2
3
4
5
6
7
8
9
10
11
12
13
14
15
16
17
18
19
20
21
22
23
24
25
26
27
28
29
30
31

Researchers are studying mechanisms of human infection by animal viruses. The investigators induce random mutations in the genome of an avian influenza virus that is unable to infect humans but is structurally similar to human influenza A virus. A mutated isolate is found to be able to infect human upper respiratory tract epithelial cells. Alteration in which of the following viral components most likely enabled this novel strain to cause cross-species infection?

A. Antigenic glycoprotein

B. Lipid bilayer envelope

C. mRNA endonuclease

D. Nucleocapsid protein

E. RNA polymerase

Submit

1
2
3
4
5
6
7
8
9
10
11
12
13
14
15
16
17
18
19
20
21
22
23
24
25
26
27
28
29
30
31

Researchers are studying mechanisms of human infection by animal viruses. The investigators induce random mutations in the genome of an avian influenza virus that is unable to infect humans but is structurally similar to human influenza A virus. A mutated isolate is found to be able to infect human upper respiratory tract epithelial cells. Alteration in which of the following viral components most likely enabled this novel strain to cause cross-species infection?

- ✓ A. Antigenic glycoprotein (57%)
- B. Lipid bilayer envelope (8%)
- C. mRNA endonuclease (4%)
- D. Nucleocapsid protein (24%)
- E. RNA polymerase (5%)

Omitted
Correct answer
A

57%
Answered correctly

02 secs
Time Spent

05/31/2020
Last Updated

Explanation

Influenza virus is a segmented, negative-sense RNA virus that is enveloped within a host-derived plasma membrane. Interaction with the host cell is dependent upon a viral **surface glycoprotein** called **hemagglutinin**, which binds to the sialic acid receptor on human respiratory epithelial cells. Influenza strains that are unable to infect humans (eg, avian/swine influenza) encode for hemagglutinin that cannot bind to human cells.

However, influenza is prone to **antigenic changes** in its surface glycoproteins due to:

- Poor proofreading of viral RNA-dependent RNA polymerase, which results in the introduction of genetic mutations during replication (antigenic drift)

1
2
3
4
5
6
7
8
9
10
11
12
13
14
15
16
17
18
19
20
21
22
23
24
25
26
27
28
29
30
31

Influenza virus is a segmented, negative-sense RNA virus that is enveloped within a host-derived plasma membrane. Interaction with the host cell is dependent upon a viral **surface glycoprotein** called **hemagglutinin**, which binds to the sialic acid receptor on human respiratory epithelial cells. Influenza strains that are unable to infect humans (eg, avian/swine influenza) encode for hemagglutinin that cannot bind to human cells.

However, influenza is prone to **antigenic changes** in its surface glycoproteins due to:

- Poor proofreading of viral RNA-dependent RNA polymerase, which results in the introduction of genetic mutations during replication (antigenic drift).
- Reassortment of the segmented genome when 2 influenza viruses infect the same cell, which results in dramatic alterations to the genome (antigenic shift).

Antigenic changes to hemagglutinin can alter the **tissue tropism** of the virus and allow strains that previously only affected livestock (eg, avian, swine) to infect human cells.

(Choice B) The influenza lipid bilayer envelope is generated from host cells during viral replication. Because it is composed of host cell lipids, it is unlikely to be significantly altered by viral mutations.

(Choices C, D, and E) Following influenza attachment and endocytosis, the viral bilayer envelope fuses with the endosome membrane, which liberates the nucleocapsid protein (bound to the RNA genome), viral RNA-dependent RNA polymerase, and viral mRNA endonuclease into the cytoplasm. These travel to the nucleus to initiate viral replication. Although mutations to these proteins could affect viral replication, they would be unlikely to alter tissue tropism because they are not on the surface of the virus and, therefore, do not mediate viral attachment.

Educational objective:
The tissue tropism of viruses is primarily mediated by viral surface glycoproteins that bind to specific host cell receptors. Mutations to viral surface glycoproteins can alter tissue tropism and cause noninfective viruses to become infectious.

Microbiology	Infectious Diseases	Influenza
Subject	System	Topic

Copyright © UWorld. All rights reserved.

1
2
3
4
5
6
7
8
9
10
11
12
13
14
15
16
17
18
19
20
21
22
23
24
25
26
27
28
29
30
31

Exhibit Display

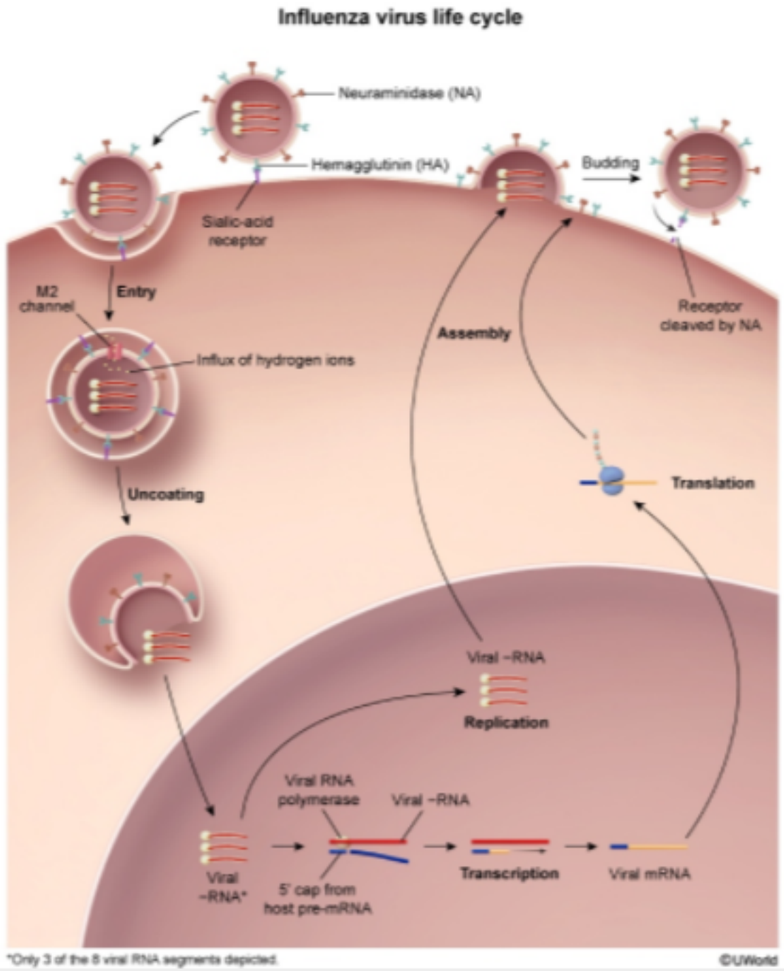

Zoom In | Zoom Out | Reset | Add To New Card | Existing Card

1
2
3
4
5
6
7
8
9
10
11
12
13
14
15
16
17
18
19
20
21
22
23
24
25
26
27
28
29
30
31

A 34-year-old woman comes to the physician complaining of fever, dysuria, and flank pain. Her temperature is 37.8 C (100 F), blood pressure is 122/78 mm Hg, and pulse is 84/min. Physical examination elicits suprapubic and costovertebral angle tenderness. Urine dipstick analysis reveals positive leukocyte esterase and nitrite. A subsequent urine culture grows colonies of motile Gram-negative rods demonstrating a green metallic sheen on eosin methylene blue (EMB) agar and hemolysis on blood agar. Which of the following is the most important bacterial factor responsible for this patient's condition?

A. Capsule

B. Heat-labile enterotoxin

C. O antigen

D. Fimbrial antigen

E. Lipid A

Submit

A 34-year-old woman comes to the physician complaining of fever, dysuria, and flank pain. Her temperature is 37.8 C (100 F), blood pressure is 122/78 mm Hg, and pulse is 84/min. Physical examination elicits suprapubic and costovertebral angle tenderness. Urine dipstick analysis reveals positive leukocyte esterase and nitrite. A subsequent urine culture grows colonies of motile Gram-negative rods demonstrating a green metallic sheen on eosin methylene blue (EMB) agar and hemolysis on blood agar. Which of the following is the most important bacterial factor responsible for this patient's condition?

- A. Capsule (14%)
- B. Heat-labile enterotoxin (6%)
- C. O antigen (6%)
- ✓ D. Fimbrial antigen (59%)
- E. Lipid A (12%)

Omitted
Correct answer
D

59%
Answered correctly

03 secs
Time Spent

07/05/2020
Last Updated

Explanation

Escherichia coli virulence factors		
Virulence factor	Mechanism	Presentation

1
2
3
4
5
6
7
8
9
10
11
12
13
14
15
16
17
18
19
20
21
22
23
24
25
26
27
28
29
30
31

***Escherichia coli* virulence factors**		
Virulence factor	**Mechanism**	**Presentation**
Lipopolysaccharide	Macrophage activation causes widespread release of IL-1, IL-6 & TNF-α	Bacteriemia & septic shock
K1 capsular polysaccharide	Prevents phagocytosis & complement-mediated lysis	Neonatal meningitis
Verotoxin (shiga-like toxin)	Inactivates the 60S ribosomal component, halting protein synthesis & causing cell death	Gastroenteritis (bloody)
Heat-stable/heat-labile enterotoxins	Promotes fluid & electrolyte secretion from intestinal epithelium	Gastroenteritis (watery)
P fimbriae	Allows adhesion to uroepithelium	Urinary tract infections

©UWorld

Escherichia coli is part of the normal bacterial flora of the intestinal tract. It is a motile, Gram-negative bacillus that is facultatively anaerobic and able to ferment both lactose and glucose. *E coli* grows well on blood, MacConkey, and eosin methylene blue (EMB) agar plates. EMB agar is a selective and differential medium used to isolate and identify enteric pathogens from contaminated clinical specimens. On EMB agar, organisms that ferment lactose, such as *E coli,* bind to dye in the agar and produce colonies that have a distinct green metallic sheen. Most strains of *E coli* also demonstrate beta-hemolysis on blood agar.

Escherichia coli is part of the normal bacterial flora of the intestinal tract. It is a motile, Gram-negative bacillus that is facultatively anaerobic and able to ferment both lactose and glucose. *E coli* grows well on blood, MacConkey, and eosin methylene blue (EMB) agar plates. EMB agar is a selective and differential medium used to isolate and identify enteric pathogens from contaminated clinical specimens. On EMB agar, organisms that ferment lactose, such as *E coli,* bind to dye in the agar and produce colonies that have a distinct green metallic sheen. Most strains of *E coli* also demonstrate beta-hemolysis on blood agar.

E coli is responsible for urinary tract infections (UTIs), neonatal meningitis, and several types of gastroenteritis. The virulence factors expressed by a particular strain of *E coli* will determine disease characteristics. **Fimbriae**, or **pili** (Type 1 fimbriae, P fimbriae, and S fimbriae), are one of the most important virulence factors expressed by *E coli*. They permit the adhesion of *E coli* to epithelial cells, uroepithelial cells, and enterocytes.

E coli causes approximately 80% of all UTIs. UTIs are more common in women than men due to the female urethra being significantly shorter. *E coli* originates in the feces and spreads to colonize the perineal, genital, and – most importantly – the periurethral regions. During sexual intercourse or bladder catheterization, *E coli* can be propelled into the urethra and bladder from the colonized periurethral region. P-fimbriae (pyelonephritis-associated pili) adhesion then allows uropathogenic *E coli* to colonize the bladder and ureters, causing cystitis and pyelonephritis.

(Choice A) *E coli* strains causing neonatal meningitis synthesize K1 capsular antigens. The K1 antigen is considered the major determinant of virulence among strains of *E coli* that cause meningitis.

(Choice B) Enterotoxigenic *E coli* produce heat-stable (ST) and/or heat labile (LT) enterotoxins. ST activates guanylate cyclase, causing an increase in cGMP. LT activates adenylate cyclase, increasing cAMP levels. In both structure and mode of action, LT is very similar to the cholera toxin.

(Choice C) The O antigen is a variable polysaccharide antigen found on the outer membrane that is used to classify Gram-negative bacteria. It is the most extracellular component of lipopolysaccharide (see Choice E).

(Choice E) The lipid A component of lipopolysaccharide is similar for all enterobacteria. Lipid A causes activation of macrophages, leading to widespread release of IL-1, IL-6, and TNF-alpha, which in turn causes the signs and symptoms of septic shock.

Educational objective:
E coli is one of the dominant components of the normal flora in the intestinal tract of humans and animals. It causes approximately 80% of all urinary tract infections. P fimbriae are the most important virulence factor that uropathogenic *E coli* express. Without P fimbriae, *E coli* would not

E coli causes approximately 80% of all UTIs. UTIs are more common in women than men due to the female urethra being significantly shorter. *E coli* originates in the feces and spreads to colonize the perineal, genital, and – most importantly – the periurethral regions. During sexual intercourse or bladder catheterization, *E coli* can be propelled into the urethra and bladder from the colonized periurethral region. P-fimbriae (pyelonephritis-associated pili) adhesion then allows uropathogenic *E coli* to colonize the bladder and ureters, causing cystitis and pyelonephritis.

(Choice A) *E coli* strains causing neonatal meningitis synthesize K1 capsular antigens. The K1 antigen is considered the major determinant of virulence among strains of *E coli* that cause meningitis.

(Choice B) Enterotoxigenic *E coli* produce heat-stable (ST) and/or heat labile (LT) enterotoxins. ST activates guanylate cyclase, causing an increase in cGMP. LT activates adenylate cyclase, increasing cAMP levels. In both structure and mode of action, LT is very similar to the cholera toxin.

(Choice C) The O antigen is a variable polysaccharide antigen found on the outer membrane that is used to classify Gram-negative bacteria. It is the most extracellular component of lipopolysaccharide (see Choice E).

(Choice E) The lipid A component of lipopolysaccharide is similar for all enterobacteria. Lipid A causes activation of macrophages, leading to widespread release of IL-1, IL-6, and TNF-alpha, which in turn causes the signs and symptoms of septic shock.

Educational objective:
E coli is one of the dominant components of the normal flora in the intestinal tract of humans and animals. It causes approximately 80% of all urinary tract infections. P fimbriae are the most important virulence factor that uropathogenic *E coli* express. Without P fimbriae, *E coli* would not be able to bind to uroepithelial cells and infect the bladder, ureters, and kidneys. Instead, the bacteria would simply be washed away during urination.

References

- Origins and virulence mechanisms of uropathogenic Escherichia coli.

Microbiology	Infectious Diseases	Urinary tract infection
Subject	System	Topic

Copyright © UWorld. All rights reserved.

1
2
3
4
5
6
7
8
9
10
11
12
13
14
15
16
17
18
19
20
21
22
23
24
25
26
27
28
29
30
31

A group of researchers collected demographic and clinical data from multiple hospitals across the nation to determine epidemiological features of nosocomial bloodstream infections. In this study, a nosocomial bloodstream infection was diagnosed if blood cultures drawn 48 hours after admission yielded a pathogenic organism. Analysis of the data collected over several decades shows that staphylococci are increasingly responsible for the identified cases. An increased use of which of the following is most likely the underlying cause of the observed trend?

A. Bioprosthetic heart valves
B. Broad-spectrum antibiotics
C. Illicit injection drugs
D. Immunomodulating therapies
E. Indwelling urinary catheters
F. Intravascular catheters

Submit

A group of researchers collected demographic and clinical data from multiple hospitals across the nation to determine epidemiological features of nosocomial bloodstream infections. In this study, a nosocomial bloodstream infection was diagnosed if blood cultures drawn 48 hours after admission yielded a pathogenic organism. Analysis of the data collected over several decades shows that staphylococci are increasingly responsible for the identified cases. An increased use of which of the following is most likely the underlying cause of the observed trend?

A. Bioprosthetic heart valves (6%)
B. Broad-spectrum antibiotics (29%)
C. Illicit injection drugs (9%)
D. Immunomodulating therapies (0%)
E. Indwelling urinary catheters (10%)
✓ F. Intravascular catheters (42%)

Omitted
Correct answer
F

42%
Answered correctly

02 secs
Time Spent

04/12/2020
Last Updated

Explanation

Most common pathogens causing nosocomial bloodstream infections
• Coagulase-negative staphylococci • *Staphylococcus aureus* • Enterococci

Most common pathogens causing nosocomial bloodstream infections
• Coagulase-negative staphylococci • *Staphylococcus aureus* • Enterococci • *Candida* species

Approximately 250,000 **nosocomial bloodstream infections** (BSIs) are estimated to occur in the United States each year. Prior to the 1980s, the leading cause was gram-negative aerobic organisms such as *Escherichia coli* that spread from primary infections in the genitourinary or gastrointestinal tract. However, the increasing use of **intravascular catheters**, which provide a portal of entry for **skin flora** to reach the bloodstream, has led to a shift in the underlying microbiology of BSI; most cases are now caused by skin commensals such as **coagulase-negative staphylococci** and ***Staphylococcus aureus***.

BSI is most common in those who have **long-term** (>12 days) central venous access as this provides sufficient time for skin flora to colonize the internal/external lumen of the catheter, to replicate within a biofilm of host (fibrin) and bacterial (glycoprotein) components, and to subsequently spread to the bloodstream. BSI should be suspected when a patient with an intravascular catheter develops new-onset fever or bacteremia.

(Choice A) Although *S aureus* is a leading cause of infective endocarditis in patients with artificial heart valves, bacteremia is much more commonly caused by intravascular devices.

(Choice B) The increased use of broad-spectrum antibiotics is associated with the development of drug-resistant organisms, including methicillin-resistant *S aureus* (MRSA). Although MRSA is a common cause of skin abscess and necrotizing pneumonia, the majority of *S aureus* bacteremia is caused by intravascular catheters.

(Choice C) Injection drug use is a major risk factor for *S aureus* abscess, bacteremia, and infective endocarditis. However, injection drug use causes far fewer BSIs than intravenous catheters.

(Choice D) Immunosuppression increases the risk of BSI due to reduced immunosurveillance. However, BSI is far more often due to the use of intravascular catheters.

(Choice E) Indwelling urinary catheters increase the risk of urinary infection with subsequent hematogenous spread of the organism. However,

Approximately 250,000 **nosocomial bloodstream infections** (BSIs) are estimated to occur in the United States each year. Prior to the 1980s, the leading cause was gram-negative aerobic organisms such as *Escherichia coli* that spread from primary infections in the genitourinary or gastrointestinal tract. However, the increasing use of **intravascular catheters**, which provide a portal of entry for **skin flora** to reach the bloodstream, has led to a shift in the underlying microbiology of BSI; most cases are now caused by skin commensals such as **coagulase-negative staphylococci** and ***Staphylococcus aureus***.

BSI is most common in those who have **long-term** (>12 days) central venous access as this provides sufficient time for skin flora to colonize the internal/external lumen of the catheter, to replicate within a biofilm of host (fibrin) and bacterial (glycoprotein) components, and to subsequently spread to the bloodstream. BSI should be suspected when a patient with an intravascular catheter develops new-onset fever or bacteremia.

(Choice A) Although *S aureus* is a leading cause of infective endocarditis in patients with artificial heart valves, bacteremia is much more commonly caused by intravascular devices.

(Choice B) The increased use of broad-spectrum antibiotics is associated with the development of drug-resistant organisms, including methicillin-resistant *S aureus* (MRSA). Although MRSA is a common cause of skin abscess and necrotizing pneumonia, the majority of *S aureus* bacteremia is caused by intravascular catheters.

(Choice C) Injection drug use is a major risk factor for *S aureus* abscess, bacteremia, and infective endocarditis. However, injection drug use causes far fewer BSIs than intravenous catheters.

(Choice D) Immunosuppression increases the risk of BSI due to reduced immunosurveillance. However, BSI is far more often due to the use of intravascular catheters.

(Choice E) Indwelling urinary catheters increase the risk of urinary infection with subsequent hematogenous spread of the organism. However, most cases are caused by gram-negative enteric organisms such as *E coli*.

Educational objective:
Nosocomial bloodstream infections are usually associated with intravascular catheters, which allow skin commensals such as *Staphylococcus aureus* and coagulase-negative staphylococci to enter the bloodstream.

Microbiology Infectious Diseases Catheter related bloodstream infection

1
2
3
4
5
6
7
8
9
10
11
12
13
14
15
16
17
18
19
20
21
22
23
24
25
26
27
28
29
30
31

A 35-year-old man is admitted to the hospital after he fell off a moving tractor and caught his right leg underneath the vehicle. The patient has no past medical history. Over the next few hours, he develops worsening severe pain and rapidly increasing swelling in the injured right leg. Crepitus is present on physical examination. Emergent radiographic imaging reveals gas in the tissues. Surgical evaluation is performed. The microorganism most likely responsible for this patient's condition is also commonly associated with which of the following conditions?

A. Heart murmur and valve abscess

B. Persistent cough and pharyngeal exudates

C. Relentless headaches and nausea

D. Transient watery diarrhea and abdominal discomfort

E. Urinary frequency and burning

Submit

A 35-year-old man is admitted to the hospital after he fell off a moving tractor and caught his right leg underneath the vehicle. The patient has no past medical history. Over the next few hours, he develops worsening severe pain and rapidly increasing swelling in the injured right leg. Crepitus is present on physical examination. Emergent radiographic imaging reveals gas in the tissues. Surgical evaluation is performed. The microorganism most likely responsible for this patient's condition is also commonly associated with which of the following conditions?

- A. Heart murmur and valve abscess (12%)
- B. Persistent cough and pharyngeal exudates (8%)
- C. Relentless headaches and nausea (5%)
- ✓ D. Transient watery diarrhea and abdominal discomfort (71%)
- E. Urinary frequency and burning (2%)

Omitted
Correct answer
D

71%
Answered correctly

01 sec
Time Spent

04/28/2020
Last Updated

Explanation

Spores of ***Clostridium perfringens***, a gram-positive bacillus responsible for ~95% of cases of **gas gangrene** (clostridial myonecrosis), are abundant in soil and can inoculate **penetrating injury** sites. On entering the host, the spores germinate in the **anaerobic** environment into vegetative cells, which produce a phospholipase **toxin** that attacks cell membranes. Extensive tissue damage, **necrosis**, and reduced blood supply to the affected area result, with the disease spreading in the enlarging anaerobic environment. The organism rapidly metabolizes carbohydrates, producing **gas** that can sometimes be felt on examination (crepitus) and may often be **visualized** on radiographs (helping to distinguish gas gangrene from other necrotizing infections). Treatment involves antibiotics and emergent debridement. However, prognosis is

1 2 3 4 5 6 7 8 9 10 11 12 13 14 15 16 17 18 19 20 21 22 23 24 25 26 27 28 29 30 31

Spores of ***Clostridium perfringens***, a gram-positive bacillus responsible for ~95% of cases of **gas gangrene** (clostridial myonecrosis), are abundant in soil and can inoculate **penetrating injury** sites. On entering the host, the spores germinate in the **anaerobic** environment into vegetative cells, which produce a phospholipase **toxin** that attacks cell membranes. Extensive tissue damage, **necrosis**, and reduced blood supply to the affected area result, with the disease spreading in the enlarging anaerobic environment. The organism rapidly metabolizes carbohydrates, producing **gas** that can sometimes be felt on examination (crepitus) and may often be **visualized** on radiographs (helping to distinguish gas gangrene from other necrotizing infections). Treatment involves antibiotics and emergent debridement. However, prognosis is poor even with prompt therapy, and tissue loss is often considerable.

C perfringens can also cause late-onset **food poisoning** that is characterized by transient watery diarrhea. This gastroenteritis is caused by a toxin formed when large quantities of clostridial spores are ingested. The spores germinate in the digestive tract and then begin to elaborate toxin, which explains the disease's delayed onset. This is in contrast to early-onset food poisoning caused by the preformed toxins of *Staphylococcus aureus* and *Bacillus cereus*.

(Choices A and B) *C perfringens* does not cause cough. It is also an extremely rare cause of endocarditis and valve abscess.

(Choice C) Relentless headaches and nausea can be caused by any organism that causes meningitis. Subacute or chronic infections causing these illnesses include *Mycobacterium tuberculosis*, *Acanthamoeba*, and *Cryptococcus neoformans*.

(Choice E) Urinary frequency and burning are caused by urethritis/cystitis. The urethritis of urinary tract infections is usually due to *Escherichia coli*, whereas sexually transmitted types of urethritis can be due to gonorrhea, chlamydia, and *Ureaplasma urealyticum*. *C perfringens* does not cause dysuria.

Educational objective:
Clostridium perfringens causes late-onset food poisoning and clostridial myonecrosis (gas gangrene). The food poisoning is toxin-mediated, late-onset, and causes transient watery diarrhea.

Microbiology	Infectious Diseases	Clostridial myonecrosis
Subject	System	Topic

Copyright © UWorld. All rights reserved.

1
2
3
4
5
6
7
8
9
10
11
12
13
14
15
16
17
18
19
20
21
22
23
24
25
26
27
28
29
30
31

A 19-year-old man comes to the office with an ulcer on his penis. The patient first noticed the lesion 3 days ago. His temperature is 37.1 C (98.8 F). Physical examination shows an indurated and painless ulcer near the glans penis, with no surrounding erythema and no inguinal lymphadenopathy. The patient is a college student. He has no significant past medical history and takes no medications. He has no known drug allergies. The first-line treatment for this patient has structural similarities with which of the following?

A. D-alanine-D-alanine

B. D-glutamic acid-D-glutamic acid

C. Folic acid

D. L-alanine-D-glutamine

E. N-acetylglucosamine

F. N-acetylmuramic acid

Submit

1
2
3
4
5
6
7
8
9
10
11
12
13
14
15
16
17
18
19
20
21
22
23
24
25
26
27
28
29
30
31

A 19-year-old man comes to the office with an ulcer on his penis. The patient first noticed the lesion 3 days ago. His temperature is 37.1 C (98.8 F). Physical examination shows an indurated and painless ulcer near the glans penis, with no surrounding erythema and no inguinal lymphadenopathy. The patient is a college student. He has no significant past medical history and takes no medications. He has no known drug allergies. The first-line treatment for this patient has structural similarities with which of the following?

- ✓ A. D-alanine-D-alanine (62%)
- B. D-glutamic acid-D-glutamic acid (5%)
- C. Folic acid (3%)
- D. L-alanine-D-glutamine (6%)
- E. N-acetylglucosamine (10%)
- F. N-acetylmuramic acid (11%)

Omitted
Correct answer
A

62%
Answered correctly

01 sec
Time Spent

04/07/2020
Last Updated

Explanation

This patient likely has a chancre due to **primary syphilis**, a sexually transmitted infection caused by the spirochete *Treponema pallidum*. Spirochetes are universally sensitive to **penicillin** because they are all gram-negative organisms with a peptidoglycan cell wall.

Penicillins work by covalently binding to and inhibiting **transpeptidase**. This enzyme catalyzes the final **cross-linking** step in peptidoglycan cell wall formation: the joining of the amino acid in the third position of a peptidoglycan molecule to the terminal D-alanine-D-alanine of another peptidoglycan molecule. The structural similarity of penicillins to D-alanine-D-alanine likely facilitates their binding to transpeptidase. When

1
2
3
4
5
6
7
8
9
10
11
12
13
14
15
16
17
18
19
20
21
22
23
24
25
26
27
28
29
30
31

Explanation

This patient likely has a chancre due to **primary syphilis**, a sexually transmitted infection caused by the spirochete *Treponema pallidum*. Spirochetes are universally sensitive to **penicillin** because they are all gram-negative organisms with a peptidoglycan cell wall.

Penicillins work by covalently binding to and inhibiting **transpeptidase**. This enzyme catalyzes the final **cross-linking** step in peptidoglycan cell wall formation: the joining of the amino acid in the third position of a peptidoglycan molecule to the terminal D-alanine-D-alanine of another peptidoglycan molecule. The structural similarity of penicillins to D-alanine-D-alanine likely facilitates their binding to transpeptidase. When transpeptidase is inhibited, cell wall synthesis ceases and cell wall degradation by bacterial autolysins proceeds unchecked. The weakened cell wall integrity causes osmotic lysis of the bacterium.

Vancomycin, a glycopeptide antibiotic, **directly** binds to the D-alanine-D-alanine residues, preventing the incorporation of new subunits into the cell wall. Vancomycin acts at an earlier stage of cell wall formation than do the penicillins.

(Choices B and D) D-glutamic acid-D-glutamic acid and L-alanine-D-glutamine are not sequences targeted by transpeptidase. Penicillin is not a structural analog of either molecule.

(Choice C) Sulfonamide antibiotics are antimetabolites that compete with para-aminobenzoic acid for incorporation into folic acid. Trimethoprim blocks another step in folic acid synthesis by inhibiting the enzyme dihydrofolate reductase.

(Choices E and F) Peptidoglycan precursor molecules consist of a disaccharide composed of N-acetylmuramic acid (MurNAc) and N-acetylglucosamine (GlcNAc).

Educational objective:
Penicillins, structurally similar to D-alanine-D-alanine, inhibit transpeptidase by binding covalently to its active site. The result is failed synthesis of the bacterial peptidoglycan cell wall.

Microbiology	Infectious Diseases	Syphilis
Subject	System	Topic

Copyright © UWorld. All rights reserved.

1
2
3
4
5
6
7
8
9
10
11
12
13
14
15
16
17
18
19
20
21
22
23
24
25
26
27
28
29
30
31

A 35-year-old homeless man comes to the emergency department due to urinary urgency, burning sensation on urination, and urethral discharge. The patient had similar symptoms 3 months ago, and urethral swab microscopy revealed numerous neutrophils and gram-negative diplococci. The symptoms resolved after treatment with ceftriaxone and azithromycin but recurred 4 days ago. The patient was advised to use condoms but has had many unprotected sexual encounters recently. He has no other medical problems. The patient occasionally drinks alcohol and smokes cigarettes. Temperature is 37.1 C (98.8 F). BMI is 18.8 kg/m^2. No suprapubic or flank tenderness is present on examination. Mild erythema is noted at the urethral meatus. Nucleic acid amplification testing of a clean catch urine specimen is positive for *Neisseria gonorrhoeae*. Which of the following is the most likely reason for the recurrence of infection in this patient?

A. Complete absence of memory T cells

B. Decreased antibody production due to malnutrition

C. High variability of microbial antigenic structure

D. Poor antigen recognition due to antigenic mimicry

E. Resistance to antimicrobial agents

Submit

1
2
3
4
5
6
7
8
9
10
11
12
13
14
15
16
17
18
19
20
21
22
23
24
25
26
27
28
29
30
31

A 35-year-old homeless man comes to the emergency department due to urinary urgency, burning sensation on urination, and urethral discharge. The patient had similar symptoms 3 months ago, and urethral swab microscopy revealed numerous neutrophils and gram-negative diplococci. The symptoms resolved after treatment with ceftriaxone and azithromycin but recurred 4 days ago. The patient was advised to use condoms but has had many unprotected sexual encounters recently. He has no other medical problems. The patient occasionally drinks alcohol and smokes cigarettes. Temperature is 37.1 C (98.8 F). BMI is 18.8 kg/m^2. No suprapubic or flank tenderness is present on examination. Mild erythema is noted at the urethral meatus. Nucleic acid amplification testing of a clean catch urine specimen is positive for *Neisseria gonorrhoeae*. Which of the following is the most likely reason for the recurrence of infection in this patient?

A. Complete absence of memory T cells (2%)

B. Decreased antibody production due to malnutrition (6%)

✓ C. High variability of microbial antigenic structure (80%)

D. Poor antigen recognition due to antigenic mimicry (3%)

E. Resistance to antimicrobial agents (6%)

Omitted
Correct answer
C

80%
Answered correctly

01 sec
Time Spent

04/19/2020
Last Updated

Explanation

Bacterial mechanisms for immune evasion

1
2
3
4
5
6
7
8
9
10
11
12
13
14
15
16
17
18
19
20
21
22
23
24
25
26
27
28
29
30
31

Bacterial mechanisms for immune evasion

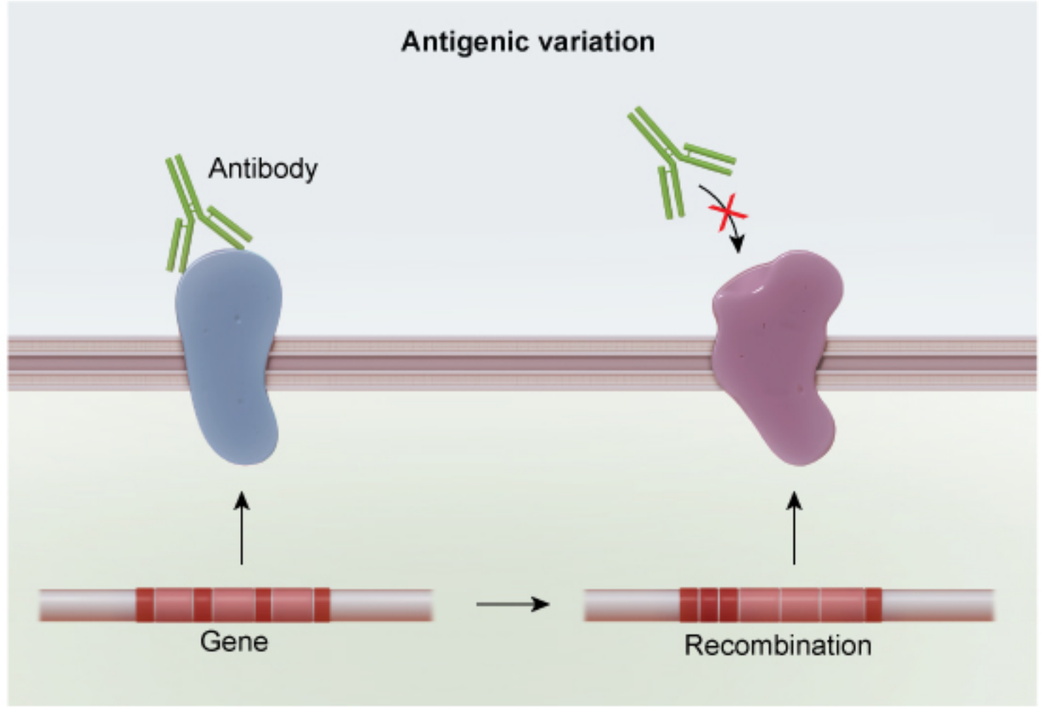

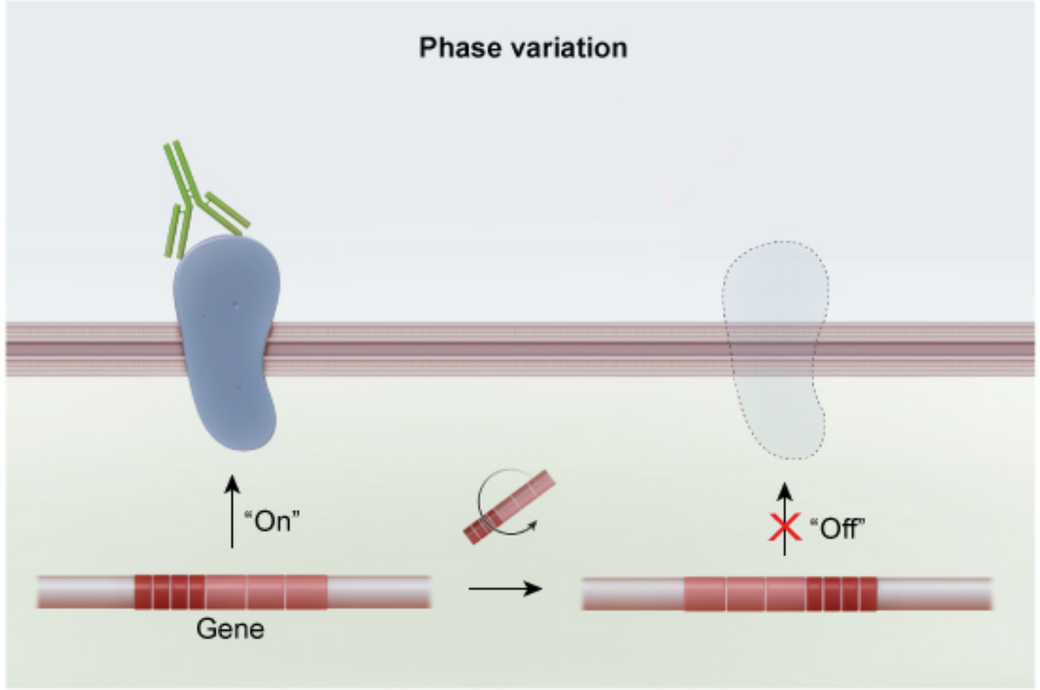

©UWorld

This patient's symptoms of **gonococcal urethritis** (dysuria, urinary discharge) resolved with ceftriaxone and then recurred several months later after unprotected sexual encounters, raising suspicion for reinfection. Although infection with *Neisseria gonorrhoeae* does lead to the formation of IgA and IgG antibodies, the **high variability of gonococcal surface antigens** (eg, porins, Opa proteins, lipooligosaccharide) limits the effectiveness of the antibody response. As such, previous infection with *N gonorrhoeae* results in almost **no protective immunity** against future infections.

(Choice A) Memory T cells form in response to gonococcal infection but are not effective at preventing reinfection due to high antigenic variation (which prevents recognition of the organism).

(Choice B) The humoral antibody response can be impaired by severe malnutrition; however, the high rate of antigenic variability in gonococcal infection would already preclude development of an effective antibody response.

This patient's symptoms of **gonococcal urethritis** (dysuria, urinary discharge) resolved with ceftriaxone and then recurred several months later after unprotected sexual encounters, raising suspicion for reinfection. Although infection with *Neisseria gonorrhoeae* does lead to the formation of IgA and IgG antibodies, the **high variability of gonococcal surface antigens** (eg, porins, Opa proteins, lipooligosaccharide) limits the effectiveness of the antibody response. As such, previous infection with *N gonorrhoeae* results in almost **no protective immunity** against future infections.

(Choice A) Memory T cells form in response to gonococcal infection but are not effective at preventing reinfection due to high antigenic variation (which prevents recognition of the organism).

(Choice B) The humoral antibody response can be impaired by severe malnutrition; however, the high rate of antigenic variability in gonococcal infection would already preclude development of an effective antibody response.

(Choice D) Antigenic mimicry occurs when an organism displays similar antigens to the host, preventing the host's immune system from recognizing the organism as foreign.

(Choice E) Gonorrhea is largely susceptible to third-generation cephalosporins (eg, ceftriaxone) but may be resistant to penicillins, macrolides, and fluoroquinolones. Antibiotic resistance should be suspected when initial symptoms do not improve with treatment. Because this patient's initial symptoms resolved after being treated with ceftriaxone and then recurred several months later, reinfection is far more likely than drug resistance. Patients with gonorrhea infection are also treated with azithromycin or doxycycline for potential *Chlamydia trachomatis* coinfection (which occurs in ~30% of patients).

Educational objective:
Neisseria gonorrhoeae has high antigenic variability of its surface molecules (eg, porins, Opa proteins), which prevents the formation of protective immunity and leads to susceptibility to repeat infection.

References

- New concepts in immunity to Neisseria Gonorrhoeae: innate responses and suppression of adaptive immunity favor the pathogen, not the host.

Microbiology | Infectious Diseases | Urethritis

1
2
3
4
5
6
7
8
9
10
11
12
13
14
15
16
17
18
19
20
21
22
23
24
25
26
27
28
29
30
31

An epidemiologic study is conducted after a sudden increase in the rate of severe postoperative infections in a rural hospital. It is determined that all the patients who developed the infection were operated on with surgical instruments sterilized by a specific autoclave machine. The machine was found to be inadequately sterilizing the equipment due to a malfunction limiting the temperature to 100 C (212 F) during the 15 minute cycle. These patients most likely developed infection from which of the following bacteria?

A. *Brucella melitensis*

B. *Clostridium perfringens*

C. *Escherichia coli*

D. *Listeria monocytogenes*

E. *Streptococcus pyogenes*

Submit

An epidemiologic study is conducted after a sudden increase in the rate of severe postoperative infections in a rural hospital. It is determined that all the patients who developed the infection were operated on with surgical instruments sterilized by a specific autoclave machine. The machine was found to be inadequately sterilizing the equipment due to a malfunction limiting the temperature to 100 C (212 F) during the 15 minute cycle. These patients most likely developed infection from which of the following bacteria?

A. *Brucella melitensis* (5%)
✓ B. *Clostridium perfringens* (69%)
C. *Escherichia coli* (12%)
D. *Listeria monocytogenes* (7%)
E. *Streptococcus pyogenes* (5%)

Omitted
Correct answer
B

69%
Answered correctly

02 secs
Time Spent

02/14/2020
Last Updated

Explanation

Autoclave machines are pressure cookers that use heated steam at temperatures of 134 C (273.2 F) to rapidly destroy pathogenic bacteria, fungi, viruses, and spores. Lower temperatures are often associated with inadequate sterilization due to the presence of **spore-forming bacteria**, which can survive at temperatures past the boiling point of water (100 C [212 F]). Bacterial spores are often found in soil and water and are resistant to chemical disinfectants, irradiation, desiccation, and temperatures as high as 120 C (248 F). ***Bacillus*** (eg, *Bacillus anthracis*) and ***Clostridium*** (eg, *Clostridium perfringens*, *C botulinum*) species are among the most common spore-forming pathogenic bacteria.

(Choices A, C, D, and E) These organisms do not form spores; vegetative bacteria are usually destroyed by temperatures >70 C (158 F).

D. *Listeria monocytogenes* (7%)

E. *Streptococcus pyogenes* (5%)

Omitted
Correct answer
B

69%
Answered correctly

02 secs
Time Spent

02/14/2020
Last Updated

Explanation

Autoclave machines are pressure cookers that use heated steam at temperatures of 134 C (273.2 F) to rapidly destroy pathogenic bacteria, fungi, viruses, and spores. Lower temperatures are often associated with inadequate sterilization due to the presence of **spore-forming bacteria**, which can survive at temperatures past the boiling point of water (100 C [212 F]). Bacterial spores are often found in soil and water and are resistant to chemical disinfectants, irradiation, desiccation, and temperatures as high as 120 C (248 F). ***Bacillus*** (eg, *Bacillus anthracis*) and ***Clostridium*** (eg, *Clostridium perfringens*, *C botulinum*) species are among the most common spore-forming pathogenic bacteria.

(Choices A, C, D, and E) These organisms do not form spores; vegetative bacteria are usually destroyed by temperatures >70 C (158 F).

Educational objective:
Spore-forming bacteria can survive boiling temperatures. *Bacillus* and *Clostridium* species are common pathogenic spore-forming bacteria.

References

- Control of bacterial spores.

Microbiology	Infectious Diseases	Infection control
Subject	System	Topic

Copyright © UWorld. All rights reserved.

1
2
3
4
5
6
7
8
9
10
11
12
13
14
15
16
17
18
19
20
21
22
23
24
25
26
27
28
29
30
31

A 29-year-old woman comes to the office due to severe joint pain in her hands, wrists, and ankles for a week. The pain is so severe that she is unable to perform her daily activities, and taking ibuprofen provides only partial relief. She has no prior medical conditions but developed high fever and diffuse rash during a trip to Puerto Rico 2 weeks ago. Evaluation at a local medical facility was negative for malaria, and her symptoms improved spontaneously after several days. She does not use tobacco, alcohol, or illicit drugs and is in a monogamous relationship with her husband. Temperature is 37 C (98.6 F), blood pressure is 122/70 mm Hg, and pulse is 86/min. Physical examination shows pink, moist oropharyngeal mucosa; no rash; clear lungs; normal heart sounds; and no abdominal organomegaly. There is periarticular swelling and tenderness of the wrists, ankles, and interphalangeal joints of her hands. Range of motion in these joints is decreased due to pain. Laboratory testing reveals lymphopenia. Which of the following is the most likely cause of this patient's joint pain?

A. Acute joint inflammation from crystal deposition

B. Immune-mediated inflammatory arthritis

C. Spondyloarthritis triggered by bacterial infection

D. Tick bite-borne spirochetal joint infection

E. Viral infection transmitted by mosquito bite

Submit

A 29-year-old woman comes to the office due to severe joint pain in her hands, wrists, and ankles for a week. The pain is so severe that she is unable to perform her daily activities, and taking ibuprofen provides only partial relief. She has no prior medical conditions but developed high fever and diffuse rash during a trip to Puerto Rico 2 weeks ago. Evaluation at a local medical facility was negative for malaria, and her symptoms improved spontaneously after several days. She does not use tobacco, alcohol, or illicit drugs and is in a monogamous relationship with her husband. Temperature is 37 C (98.6 F), blood pressure is 122/70 mm Hg, and pulse is 86/min. Physical examination shows pink, moist oropharyngeal mucosa; no rash; clear lungs; normal heart sounds; and no abdominal organomegaly. There is periarticular swelling and tenderness of the wrists, ankles, and interphalangeal joints of her hands. Range of motion in these joints is decreased due to pain. Laboratory testing reveals lymphopenia. Which of the following is the most likely cause of this patient's joint pain?

- A. Acute joint inflammation from crystal deposition (0%)
- B. Immune-mediated inflammatory arthritis (24%)
- C. Spondyloarthritis triggered by bacterial infection (13%)
- D. Tick bite-borne spirochetal joint infection (16%)
- ✓ E. Viral infection transmitted by mosquito bite (45%)

Omitted
Correct answer
E

45%
Answered correctly

02 secs
Time Spent

02/09/2020
Last Updated

Explanation

Chikungunya fever	

Chikungunya fever	
Epidemiology	• Tropical/subtropical parts of Central/South America, Africa & Asia • Vector: *Aedes* **mosquito** (also transmits dengue & Zika)
Manifestations	• Incubation period: 3-7 days • High fevers & **severe polyarthralgias** (almost always present) • Headache, myalgias, conjunctivitis, maculopapular rash • Lymphopenia, thrombocytopenia, transaminitis
Management	• Supportive care (initial symptoms usually resolve in 7-10 days) • **Chronic arthralgias/arthritis** occurs in >50% (may require methotrexate)

This patient's transient febrile illness and rash followed by severe polyarthritis raise strong suspicion for **chikungunya**, an **alphavirus** transmitted to humans by *Aedes* **mosquitos** during blood feeding. Outbreaks are common in tropical and subtropical climates (eg, **Puerto Rico**, Africa, Asia, Indian/Pacific islands) during the rainy season and may be brought back to the United States by travelers.

Chikungunya means "stooped walk" because the hallmark of the disease is **severe joint symptoms**. Manifestations generally begin a few days after transmission with high fever, symmetric **polyarticular arthralgia**, and a maculopapular rash. Lymphopenia and thrombocytopenia commonly occur. Initial symptoms usually abate completely within days, but >50% of individuals develop relapsed/chronic arthralgia, **polyarticular arthritis** (particularly of the wrists/hands/ankles), or tenosynovitis in the following weeks or months. Because *Aedes* mosquitos also transmit dengue and Zika viruses, coinfection can occur.

(Choice A) Gout causes recurrent, acute joint inflammation due to monosodium urate crystal deposition. However, most cases are monoarticular and occur in lower extremity joints.

(Choice B) Rheumatoid arthritis is an immune-mediated disorder that causes symmetric, inflammatory polyarthritis with eventual joint destruction. Patients generally develop morning stiffness followed by joint swelling in the fingers, wrists, and toes. Given this patient's young age, febrile illness with rash during recent travel, and lymphopenia, chikungunya is more likely.

(Choice C) Reactive arthritis is a rare condition that primarily occurs following a gastrointestinal (eg, *Salmonella*, *Shigella*, *Campylobacter*) or genital (eg, *Chlamydia*) bacterial infection. Manifestations typically include an asymmetric oligoarthritis that often affects the knees. This patient's

to humans by *Aedes* **mosquitos** during blood feeding. Outbreaks are common in tropical and subtropical climates (eg, **Puerto Rico**, Africa, Asia, Indian/Pacific islands) during the rainy season and may be brought back to the United States by travelers.

Chikungunya means "stooped walk" because the hallmark of the disease is **severe joint symptoms**. Manifestations generally begin a few days after transmission with high fever, symmetric **polyarticular arthralgia**, and a maculopapular rash. Lymphopenia and thrombocytopenia commonly occur. Initial symptoms usually abate completely within days, but >50% of individuals develop relapsed/chronic arthralgia, **polyarticular arthritis** (particularly of the wrists/hands/ankles), or tenosynovitis in the following weeks or months. Because *Aedes* mosquitos also transmit dengue and Zika viruses, coinfection can occur.

(Choice A) Gout causes recurrent, acute joint inflammation due to monosodium urate crystal deposition. However, most cases are monoarticular and occur in lower extremity joints.

(Choice B) Rheumatoid arthritis is an immune-mediated disorder that causes symmetric, inflammatory polyarthritis with eventual joint destruction. Patients generally develop morning stiffness followed by joint swelling in the fingers, wrists, and toes. Given this patient's young age, febrile illness with rash during recent travel, and lymphopenia, chikungunya is more likely.

(Choice C) Reactive arthritis is a rare condition that primarily occurs following a gastrointestinal (eg, *Salmonella*, *Shigella*, *Campylobacter*) or genital (eg, *Chlamydia*) bacterial infection. Manifestations typically include an asymmetric oligoarthritis that often affects the knees. This patient's symmetric polyarthritis following a febrile illness while traveling makes chikungunya far more likely.

(Choice D) Lyme disease is caused by the spirochete *Borrelia burgdorferi*. Initial symptoms can include fever, malaise, and a spreading, annular rash (erythema migrans). Several months or years later, late manifestations such as monoarticular arthritis of the knee or asymmetric oligoarthritis can also occur. This patient's polyarticular arthritis developing a few weeks after a febrile illness makes chikungunya far more likely.

Educational objective:
Chikungunya is an alphavirus spread by mosquitos to humans in tropical and subtropical areas. Initial manifestations include self-limited fever, severe polyarthralgia, and rash. Relapsed or chronic arthralgias, polyarthritis (eg, wrist, fingers, ankles), or tenosynovitis occur in >50% of infected individuals.

References

- Chikungunya infection: a re-emerging epidemic.

A 22-year-old woman comes to the emergency department with fevers and arthralgias. She recently had unprotected sexual intercourse with a new male partner. Her temperature is 38.4 C (101.1 F), blood pressure is 118/76 mm Hg, pulse is 102/min, and respirations are 16/min. Examination shows several pustules on the dorsal aspects of her forearms. Her right wrist and ankle are tender on palpation. Gram-negative bacteria isolated from this patient's blood produce an enzyme that splits the IgA molecule at the hinge region. Which of the following is likely to be the most important role of this bacterial enzyme in the course of the infection?

- A. It facilitates mucosal adherence of bacteria
- B. It impairs complement-mediated cell lysis
- C. It impairs opsonization and phagocytosis
- D. It impairs secondary immune response generation
- E. It promotes intracellular survival

Submit

A 22-year-old woman comes to the emergency department with fevers and arthralgias. She recently had unprotected sexual intercourse with a new male partner. Her temperature is 38.4 C (101.1 F), blood pressure is 118/76 mm Hg, pulse is 102/min, and respirations are 16/min. Examination shows several pustules on the dorsal aspects of her forearms. Her right wrist and ankle are tender on palpation. Gram-negative bacteria isolated from this patient's blood produce an enzyme that splits the IgA molecule at the hinge region. Which of the following is likely to be the most important role of this bacterial enzyme in the course of the infection?

- ✓ A. It facilitates mucosal adherence of bacteria (59%)
- B. It impairs complement-mediated cell lysis (8%)
- C. It impairs opsonization and phagocytosis (23%)
- D. It impairs secondary immune response generation (5%)
- E. It promotes intracellular survival (3%)

Omitted
Correct answer
A

59%
Answered correctly

01 sec
Time Spent

02/17/2020
Last Updated

Explanation

This patient likely has disseminated gonorrheal infection (triad of arthritis, dermatitis, and tenosynovitis in a sexually active woman) due to *Neisseria gonorrhoeae*. In mucosal regions as well as in secretions, IgA exists in its secretory form, composed of an IgA dimer (joined by a peptide J chain) and a peptide secretory component. IgA antibodies usually bind to pili and other membrane proteins involved in bacterial adherence to mucosa, thus inhibiting mucosal colonization by the microorganism.

Certain bacteria (eg, *N gonorrhoeae, N meningitidis, Streptococcus pneumoniae, Haemophilus influenzae*) produce **IgA proteases** that cleave IgA

Explanation

This patient likely has disseminated gonorrheal infection (triad of arthritis, dermatitis, and tenosynovitis in a sexually active woman) due to *Neisseria gonorrhoeae*. In mucosal regions as well as in secretions, IgA exists in its secretory form, composed of an IgA dimer (joined by a peptide J chain) and a peptide secretory component. IgA antibodies usually bind to pili and other membrane proteins involved in bacterial adherence to mucosa, thus inhibiting mucosal colonization by the microorganism.

Certain bacteria (eg, *N gonorrhoeae, N meningitidis, Streptococcus pneumoniae, Haemophilus influenzae*) produce **IgA proteases** that cleave IgA at its hinge region (yielding Fab and compromised Fc fragments), thus decreasing its effectiveness. This facilitates **bacterial adherence to mucosa** (possibly due to easier bacterial access to mucosal surface or immune disguise by binding to released Fab fragments, among others).

(Choice B) IgA is a weak activator of the classic complement pathway. Impairment of complement-mediated cell lysis can be accomplished by staphylococcal protein A, which binds the Fc portion of IgG, preventing complement fixation.

(Choice C) Although IgA Fc-mediated functions such as opsonization are compromised by IgA protease, secretory IgA is a poor opsonin. Impairment of opsonization and phagocytosis is most frequently accomplished by encapsulated bacteria such as *S pneumoniae, N meningitidis*, and *H influenzae*.

(Choice D) IgA does not play a role in the induction of memory lymphocytes necessary for mounting a secondary immune response (which requires the formation of memory B and T lymphocytes after initial antigen exposure).

(Choice E) Promotion of intracellular survival is accomplished by inhibition of phagosome-lysosome fusion or resistance to lysosomal enzymes. These properties are expressed by *Mycobacterium tuberculosis, M leprae, Legionella*, and *Ehrlichia*.

Educational objective:
IgA protease is produced by *Neisseria meningitidis, N gonorrhoeae, Streptococcus pneumoniae*, and *Haemophilus influenzae*. This enzyme cleaves secretory IgA at its hinge region, rendering it ineffective. Secretory IgA exists on mucosal surfaces and in secretions and acts to bind and inhibit the action of pili as well as other cell surface antigens that normally mediate mucosal adherence and subsequent penetration.

References

- Working mechanism of immunoglobulin A1 (IgA1) protease: Cleavage of IgA1 antibody to Neisseria meningitidis porA requires de novo synthesis of IgA1 protease.

Explanation

Exhibit Display

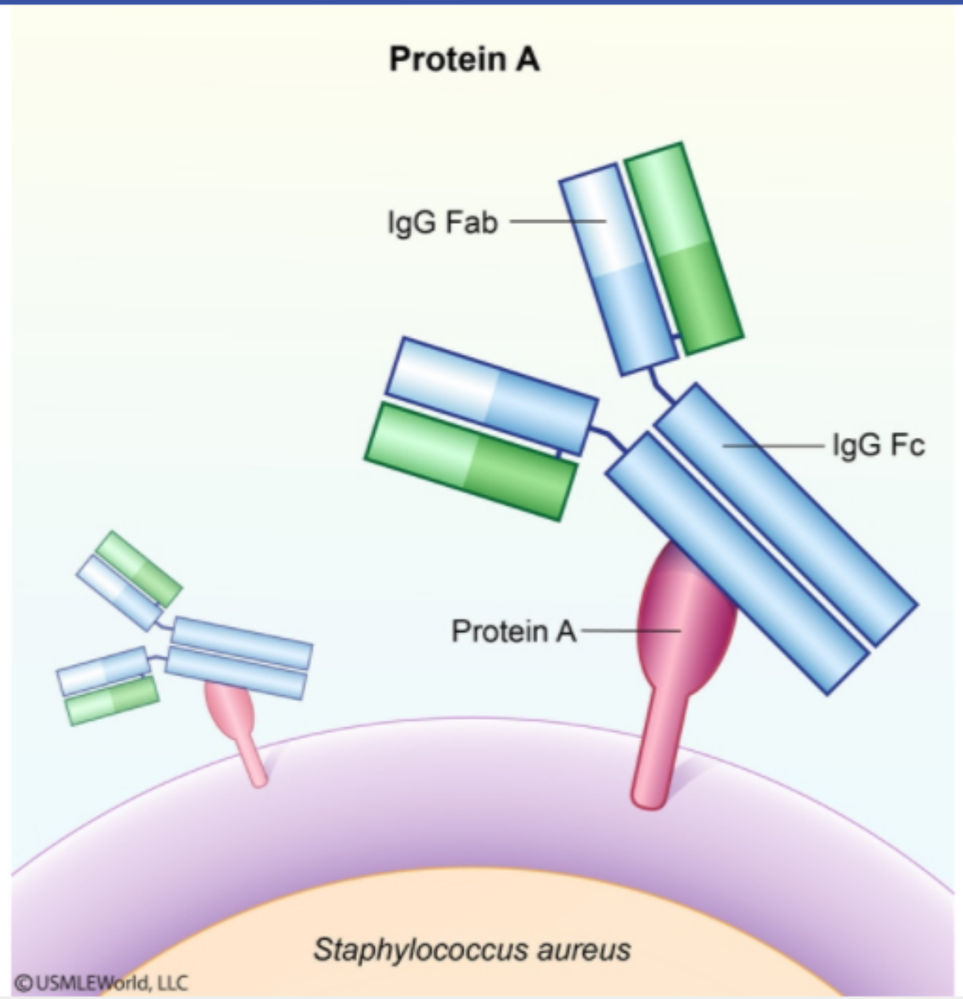

Zoom In | Zoom Out | Reset | Add To New Card | Existing Card

synthesis of IgA1 protease.

A 52-year-old man is brought to the emergency department due to worsening right leg pain, fever, and confusion. The patient injured his leg while operating a motorized watercraft on the ocean near Florida 2 days ago. Temperature is 38.9 C (102 F), blood pressure is 90/50 mm Hg, and pulse is 120/min. The patient is lethargic and diaphoretic. Physical examination reveals a small laceration on the dorsum of the right foot with surrounding edema, erythema, and several hemorrhagic bullae. Leukocyte count and serum lactic acid levels are elevated. Intravenous fluids and empiric antibiotics are administered, and surgical debridement of the wound is performed. Blood and wound cultures yield curved gram-negative rods. Which of the following is the greatest risk factor for this patient's infection?

A. Bacterial nasal colonization

B. Condition causing iron overload

C. Exposure to infected rodent urine

D. Lack of booster immunization

E. Recent broad-spectrum antibiotic use

Submit

A 52-year-old man is brought to the emergency department due to worsening right leg pain, fever, and confusion. The patient injured his leg while operating a motorized watercraft on the ocean near Florida 2 days ago. Temperature is 38.9 C (102 F), blood pressure is 90/50 mm Hg, and pulse is 120/min. The patient is lethargic and diaphoretic. Physical examination reveals a small laceration on the dorsum of the right foot with surrounding edema, erythema, and several hemorrhagic bullae. Leukocyte count and serum lactic acid levels are elevated. Intravenous fluids and empiric antibiotics are administered, and surgical debridement of the wound is performed. Blood and wound cultures yield curved gram-negative rods. Which of the following is the greatest risk factor for this patient's infection?

- A. Bacterial nasal colonization (6%)
- ✓ B. Condition causing iron overload (23%)
- C. Exposure to infected rodent urine (30%)
- D. Lack of booster immunization (24%)
- E. Recent broad-spectrum antibiotic use (14%)

Omitted
Correct answer
B

23%
Answered correctly

02 secs
Time Spent

04/15/2020
Last Updated

Explanation

Vibrio vulnificus	
Epidemiology	• Curved, gram-negative, free-living in **salt water** • High concentrations in warm months

Vibrio vulnificus	
Epidemiology	• Curved, gram-negative, free-living in **salt water** • High concentrations in warm months • Ingestion (**raw oysters**) or wound infection • ↑ Risk in those with **liver disease** & **iron overload***
Manifestations	• Rapidly progressive (often <12 hours) • **Septicemia** – Septic shock, bullous lesions • **Cellulitis** – Hemorrhagic bullae, necrotizing fasciitis

*Hereditary hemochromatosis is particularly high risk as iron acts as a growth catalyst.

Vibrio vulnificus is a curved, gram-negative, free-living bacterium that grows in brackish coastal water and **marine** environments. This bacterium is found in greatest concentrations in the summer months, comprising as much as 8% of the total bacteria in some areas. *V vulnificus* infections are primarily acquired through the consumption of **raw oysters** (which concentrate the bacterium) or **wound contamination** during recreational water activities or the handling of raw seafood. Most patients who become ill have **liver disease** (eg, alcoholic cirrhosis, viral hepatitis); those with **iron overload** (eg, hemochromatosis) are at particularly high risk as free iron acts as an exponential growth catalyst for the bacterium.

Healthy patients with *V vulnificus* wound contamination usually develop a mild cellulitis, but those with iron overload or liver disease are at high risk for **rapidly progressive necrotizing fasciitis** with hemorrhagic, bullous lesions and septic shock (eg, hypotension, elevated lactic acid level). In these patients, urgent antibiotics, surgery, and blood pressure support are usually required to prevent death.

(Choice A) *Staphylococcus aureus* colonizes the nasopharynx and is a leading cause of skin/soft-tissue abscess. However, *S aureus* is a catalase-positive, gram-positive bacterium.

(Choice C) *Leptospira* species are highly motile, gram-negative spirochetes that are often transmitted via contaminated rat urine. Leptospirosis is often mild or asymptomatic but may cause fever, myalgia, headache, multiorgan failure, or death. This patient who developed symptoms after a sustaining a wound while boating is more likely to have a *V vulnificus* infection.

(Choice D) *Clostridium tetani* is an anaerobic, gram-positive, spore-forming rod-shaped bacterium that can inoculate wounds contaminated with

Vibrio vulnificus is a curved, gram-negative, free-living bacterium that grows in brackish coastal water and **marine** environments. This bacterium is found in greatest concentrations in the summer months, comprising as much as 8% of the total bacteria in some areas. *V vulnificus* infections are primarily acquired through the consumption of **raw oysters** (which concentrate the bacterium) or **wound contamination** during recreational water activities or the handling of raw seafood. Most patients who become ill have **liver disease** (eg, alcoholic cirrhosis, viral hepatitis); those with **iron overload** (eg, hemochromatosis) are at particularly high risk as free iron acts as an exponential growth catalyst for the bacterium.

Healthy patients with *V vulnificus* wound contamination usually develop a mild cellulitis, but those with iron overload or liver disease are at high risk for **rapidly progressive necrotizing fasciitis** with hemorrhagic, bullous lesions and septic shock (eg, hypotension, elevated lactic acid level). In these patients, urgent antibiotics, surgery, and blood pressure support are usually required to prevent death.

(Choice A) *Staphylococcus aureus* colonizes the nasopharynx and is a leading cause of skin/soft-tissue abscess. However, *S aureus* is a catalase-positive, gram-positive bacterium.

(Choice C) *Leptospira* species are highly motile, gram-negative spirochetes that are often transmitted via contaminated rat urine. Leptospirosis is often mild or asymptomatic but may cause fever, myalgia, headache, multiorgan failure, or death. This patient who developed symptoms after a sustaining a wound while boating is more likely to have a *V vulnificus* infection.

(Choice D) *Clostridium tetani* is an anaerobic, gram-positive, spore-forming rod-shaped bacterium that can inoculate wounds contaminated with soil. It elaborates an exotoxin (tetanus toxin) that disinhibits anterior horn cells and results in painful muscle contractions, lock-jaw, and difficulty swallowing.

(Choice E) *Clostridium difficile* is most common in individuals who have recently taken broad-spectrum antibiotics, which disrupts gastrointestinal flora and allows the organism to proliferate. Patients usually develop diarrhea, fever, and abdominal pain.

Educational objective:
Vibrio vulnificus is a curved, gram-negative, free-living bacterium that grows in marine environments. Transmission primarily occurs due to the consumption of raw seafood (eg, oysters) or wound contamination. Manifestations are often mild, but individuals with liver disease or iron overload are at very high risk of severe, fulminant infection (eg, sepsis, necrotizing fascitis).

Microbiology	Infectious Diseases	Vibrio vulnificus
Subject	System	Topic

Vibrio vulnificus is a curved, gram-negative, free-living bacterium that grows in brackish coastal water and **marine** environments. This bacterium

Exhibit Display

Zoom In | Zoom Out | Reset | Add To New Card | Existing Card

Microbiology | Infectious Diseases | Vibrio vulnificus
Subject | System | Topic

A 72-year-old man is brought to the emergency department from a skilled nursing facility due to altered mental status, skin flushing, and a high fever. His temperature is 38.9 C (102 F), blood pressure is 80/40 mm Hg, pulse is 120/min, and respirations are 26/min. If blood cultures are positive for *Escherichia coli*, which of the following is the most likely site of infection leading to bacteremia in this patient?

- A. Biliary tree
- B. Colon
- C. Lungs
- D. Oropharynx
- E. Skin
- F. Small intestine
- G. Urinary tract

Submit

A 72-year-old man is brought to the emergency department from a skilled nursing facility due to altered mental status, skin flushing, and a high fever. His temperature is 38.9 C (102 F), blood pressure is 80/40 mm Hg, pulse is 120/min, and respirations are 26/min. If blood cultures are positive for *Escherichia coli*, which of the following is the most likely site of infection leading to bacteremia in this patient?

- A. Biliary tree (1%)
- B. Colon (6%)
- C. Lungs (1%)
- D. Oropharynx (1%)
- E. Skin (0%)
- F. Small intestine (4%)
- ✓ G. Urinary tract (83%)

Omitted
Correct answer
G

83%
Answered correctly

02 secs
Time Spent

02/16/2020
Last Updated

Explanation

This elderly patient with fever, hypotension, altered mental status, and *Escherichia coli* bacteremia has septic shock most likely due to **urinary tract infection (UTI)**. UTIs are a common cause of sudden disorientation or confusion in the elderly. Predisposing factors include urinary obstruction (eg, benign prostatic hypertrophy), fecal incontinence, neurogenic bladder (eg, due to diabetes), and frequent or indwelling catheterization. *E coli* is the most common organism causing UTI (others are *Proteus, Klebsiella, Enterobacter, Citrobacter*, and *Pseudomonas*),

This elderly patient with fever, hypotension, altered mental status, and *Escherichia coli* bacteremia has septic shock most likely due to **urinary tract infection (UTI)**. UTIs are a common cause of sudden disorientation or confusion in the elderly. Predisposing factors include urinary obstruction (eg, benign prostatic hypertrophy), fecal incontinence, neurogenic bladder (eg, due to diabetes), and frequent or indwelling catheterization. *E coli* is the most common organism causing UTI (others are *Proteus, Klebsiella, Enterobacter, Citrobacter*, and *Pseudomonas*), and UTIs represent the most common cause of ***E coli* bacteremia**. *E coli* is part of the normal gastrointestinal (GI) flora. Some strains have adhesive fimbriae allowing them to potentially contaminate the urethra and ascend the urinary tract, leading to UTI or pyelonephritis.

Gram-negative sepsis or septic shock can ensue as a result of the body's systemic reaction to lipopolysaccharide endotoxin (a component in some gram-negative bacterial membranes). Signs of **sepsis** include hyper- or hypothermia, tachycardia, tachypnea (can lead to respiratory alkalosis), and leukocytosis. Severe sepsis is marked by **organ dysfunction** due to poor blood flow (eg, oliguria from poor renal perfusion and altered mental status from poor cerebral perfusion). Metabolic lactic acidosis can be seen, particularly during the late stages, due to poor tissue perfusion. Treatment is focused on maintaining blood pressure and organ perfusion with intravenous fluids, administering antibiotics directed against the offending organism, and maintaining proper ventilation and oxygenation.

(Choice A) The biliary tree has many protective mechanisms against bacterial colonization and infection. The sphincter of Oddi prevents reflux of nonsterile duodenal contents into the biliary tree, bile salts can inhibit bacterial growth, downstream biliary flow helps to wash organisms away from the biliary tree, and bile secretory IgA helps to prevent bacterial adherence. Despite this, organisms such as *E coli, Klebsiella, Enterobacter*, and enterococci occasionally infect the biliary tract, leading to cholangitis that can cause sepsis if left untreated. However, this process is a much less frequent cause of bacteremia than UTI, and cholangitis classically presents with fever, abdominal pain, and jaundice.

(Choices B and F) Many microorganisms inhabit the human GI tract as normal flora. Under normal circumstances, small intestine bacteria do not cause systemic disease. Anaerobic or gram-negative rod bacteremia can result from colonic perforation due to surgery, trauma, or wall rupture from certain pathologic processes. However, the likely site of infection in this patient with *E coli* bacteremia is the genitourinary tract; although it may represent the ultimate site of origin of *E coli*, the GI tract is not typically a site of infection.

(Choices C and D) Bacterial causes of upper respiratory tract infection (eg, *Moraxella* and *Haemophilus*) do not usually cause disseminated disease. *E coli* and other gram-negative rods (*Pseudomonas, Acinetobacter*, and *Klebsiella*) would be common causes of health care-acquired pneumonia in this nursing home resident; from the lungs, these organisms can easily gain access to the bloodstream and cause sepsis. However, this patient does not have any respiratory symptoms, and *E coli* sepsis is more commonly due to UTI than pneumonia.

perfusion. Treatment is focused on maintaining blood pressure and organ perfusion with intravenous fluids, administering antibiotics directed against the offending organism, and maintaining proper ventilation and oxygenation.

(Choice A) The biliary tree has many protective mechanisms against bacterial colonization and infection. The sphincter of Oddi prevents reflux of nonsterile duodenal contents into the biliary tree, bile salts can inhibit bacterial growth, downstream biliary flow helps to wash organisms away from the biliary tree, and bile secretory IgA helps to prevent bacterial adherence. Despite this, organisms such as *E coli, Klebsiella, Enterobacter*, and enterococci occasionally infect the biliary tract, leading to cholangitis that can cause sepsis if left untreated. However, this process is a much less frequent cause of bacteremia than UTI, and cholangitis classically presents with fever, abdominal pain, and jaundice.

(Choices B and F) Many microorganisms inhabit the human GI tract as normal flora. Under normal circumstances, small intestine bacteria do not cause systemic disease. Anaerobic or gram-negative rod bacteremia can result from colonic perforation due to surgery, trauma, or wall rupture from certain pathologic processes. However, the likely site of infection in this patient with *E coli* bacteremia is the genitourinary tract; although it may represent the ultimate site of origin of *E coli*, the GI tract is not typically a site of infection.

(Choices C and D) Bacterial causes of upper respiratory tract infection (eg, *Moraxella* and *Haemophilus*) do not usually cause disseminated disease. *E coli* and other gram-negative rods (*Pseudomonas, Acinetobacter*, and *Klebsiella*) would be common causes of health care-acquired pneumonia in this nursing home resident; from the lungs, these organisms can easily gain access to the bloodstream and cause sepsis. However, this patient does not have any respiratory symptoms, and *E coli* sepsis is more commonly due to UTI than pneumonia.

(Choice E) Normal skin flora includes mostly gram-positive organisms such as staphylococci and streptococci.

Educational objective:
Escherichia coli is the most common cause of urinary tract infection (UTI) in both healthy adults and elderly patients. *E coli* is a part of the normal gastrointestinal flora, and special adhesive proteins (fimbriae) allow some strains to colonize and ascend the urinary tract. This can result in UTI, pyelonephritis, or bacteremia and sepsis following access to the bloodstream. UTIs are the most common cause of *E coli* bacteremia.

Microbiology	Infectious Diseases	Urinary tract infection
Subject	System	Topic

Copyright © UWorld. All rights reserved.

A 32-year-old man comes to the office due to 2 weeks of fever, malaise, and arthralgia. Temperature is 38.2 C (100.8 F) and pulse is 102/min. Physical examination reveals several enlarged cervical, axillary, and inguinal lymph nodes and a diffuse maculopapular skin rash. Serum aminotransferase levels are elevated. During further testing, the patient's serum is added to a mixture of cardiolipin, cholesterol, and lecithin, which leads to extensive clumping and flocculation. Evaluation for antibodies directed against which of the following is the best next step in management of this patient?

A. *Borrelia burgdorferi*

B. Fc portion of IgG

C. *Histoplasma capsulatum*

D. Mitochondrial components

E. *Treponema pallidum*

Submit

A 32-year-old man comes to the office due to 2 weeks of fever, malaise, and arthralgia. Temperature is 38.2 C (100.8 F) and pulse is 102/min. Physical examination reveals several enlarged cervical, axillary, and inguinal lymph nodes and a diffuse maculopapular skin rash. Serum aminotransferase levels are elevated. During further testing, the patient's serum is added to a mixture of cardiolipin, cholesterol, and lecithin, which leads to extensive clumping and flocculation. Evaluation for antibodies directed against which of the following is the best next step in management of this patient?

- A. *Borrelia burgdorferi* (13%)
- B. Fc portion of IgG (16%)
- C. *Histoplasma capsulatum* (4%)
- D. Mitochondrial components (8%)
- ✓ E. *Treponema pallidum* (56%)

Omitted
Correct answer
E

56%
Answered correctly

02 secs
Time Spent

01/20/2020
Last Updated

Explanation

Syphilis: diagnostic serology	
Nontreponemal (RPR, VDRL)	• Antibody to **cardiolipin-cholesterol-lecithin antigen** • Lower sensitivity in early infection
Treponemal	• Antibody to **treponemal antigens**

Syphilis: diagnostic serology	
Nontreponemal (RPR, VDRL)	• Antibody to **cardiolipin-cholesterol-lecithin antigen** • Lower sensitivity in early infection
Treponemal (FTA-ABS, TP-EIA)	• Antibody to **treponemal antigens** • Greater sensitivity in early infection

FTA-ABS = fluorescent treponemal antibody-absorption (test); **RPR** = rapid plasma reagin (test); **TP-EIA** = *Treponema pallidum* enzyme immunoassay.

This patient has fever, arthralgias, diffuse lymphadenopathy, elevated aminotransferases, and widespread maculopapular rash raising suspicion for secondary syphilis. Syphilis is a multistage infection caused by the spirochete ***Treponema pallidum***. Diagnostic screening and confirmation rely primarily on serologic testing.

Nontreponemal serologic tests (rapid plasma reagin, VDRL) mix a patient's serum with a cardiolipin-cholesterol-lecithin antigen. Aggregation or flocculation (clumping) indicates the presence of **anticardiolipin antibodies** in the patient's serum. These antibodies form in response to the release of lipids from cells damaged by *T pallidum*. However, anticardiolipin antibodies are **nonspecific**; they can also develop in other treponemal (eg, yaws, pinta, bejel) and nontreponemal (eg, tuberculosis) infections and certain rheumatologic diseases (eg, lupus), which can lead to false-positive results.

Positive nontreponemal screening requires diagnostic confirmation with **treponemal serologic testing** (eg, fluorescent treponemal antibody-absorption). Treponemal tests evaluate for **antibodies that directly target *T pallidum***; patient serum is mixed with killed *T pallidum* to evaluate for antibody adherence using immunofluorescence. Patients with positive nontreponemal and treponemal tests are considered infected with syphilis.

(Choice A) Lyme disease is caused by the spirochete *Borrelia burgdorferi*. Patients with early Lyme disease often develop flulike symptoms and a bull's-eye rash (not a diffuse maculopapular rash). Serologic testing for IgM/IgG against *Borrelia* can aid in the diagnosis as the disease progresses.

(Choice B) Rheumatoid factor is an antibody that targets the Fc portion of IgG. Elevations are often seen in patients with rheumatoid arthritis and other autoimmune diseases.

This patient has fever, arthralgias, diffuse lymphadenopathy, elevated aminotransferases, and widespread maculopapular rash raising suspicion for secondary syphilis. Syphilis is a multistage infection caused by the spirochete ***Treponema pallidum***. Diagnostic screening and confirmation rely primarily on serologic testing.

Nontreponemal serologic tests (rapid plasma reagin, VDRL) mix a patient's serum with a cardiolipin-cholesterol-lecithin antigen. Aggregation or flocculation (clumping) indicates the presence of **anticardiolipin antibodies** in the patient's serum. These antibodies form in response to the release of lipids from cells damaged by *T pallidum*. However, anticardiolipin antibodies are **nonspecific**; they can also develop in other treponemal (eg, yaws, pinta, bejel) and nontreponemal (eg, tuberculosis) infections and certain rheumatologic diseases (eg, lupus), which can lead to false-positive results.

Positive nontreponemal screening requires diagnostic confirmation with **treponemal serologic testing** (eg, fluorescent treponemal antibody-absorption). Treponemal tests evaluate for **antibodies that directly target *T pallidum***; patient serum is mixed with killed *T pallidum* to evaluate for antibody adherence using immunofluorescence. Patients with positive nontreponemal and treponemal tests are considered infected with syphilis.

(Choice A) Lyme disease is caused by the spirochete *Borrelia burgdorferi*. Patients with early Lyme disease often develop flulike symptoms and a bull's-eye rash (not a diffuse maculopapular rash). Serologic testing for IgM/IgG against *Borrelia* can aid in the diagnosis as the disease progresses.

(Choice B) Rheumatoid factor is an antibody that targets the Fc portion of IgG. Elevations are often seen in patients with rheumatoid arthritis and other autoimmune diseases.

(Choice C) *Histoplasma capsulatum* infection can be diagnosed by examining urine and serum for fungal antigens. *Histoplasma* infections usually present with prominent pulmonary manifestations rather than diffuse rash and lymphadenopathy.

(Choice D) Antimitochondrial antibodies are present in >95% of cases of primary biliary cholangitis, which usually causes fatigue, pruritus, hepatomegaly, and elevated alkaline phosphatase. This patient's systemic maculopapular rash and diffuse lymphadenopathy make syphilis more likely.

Educational objective:
Syphilis is caused by the spirochete *Treponema pallidum*. Confirmation of the diagnosis requires 2 forms of serologic testing to prevent false-

treponemal (eg, yaws, pinta, bejel) and nontreponemal (eg, tuberculosis) infections and certain rheumatologic diseases (eg, lupus), which can lead to false-positive results.

Positive nontreponemal screening requires diagnostic confirmation with **treponemal serologic testing** (eg, fluorescent treponemal antibody-absorption). Treponemal tests evaluate for **antibodies that directly target *T pallidum***; patient serum is mixed with killed *T pallidum* to evaluate for antibody adherence using immunofluorescence. Patients with positive nontreponemal and treponemal tests are considered infected with syphilis.

(Choice A) Lyme disease is caused by the spirochete *Borrelia burgdorferi*. Patients with early Lyme disease often develop flulike symptoms and a bull's-eye rash (not a diffuse maculopapular rash). Serologic testing for IgM/IgG against *Borrelia* can aid in the diagnosis as the disease progresses.

(Choice B) Rheumatoid factor is an antibody that targets the Fc portion of IgG. Elevations are often seen in patients with rheumatoid arthritis and other autoimmune diseases.

(Choice C) *Histoplasma capsulatum* infection can be diagnosed by examining urine and serum for fungal antigens. *Histoplasma* infections usually present with prominent pulmonary manifestations rather than diffuse rash and lymphadenopathy.

(Choice D) Antimitochondrial antibodies are present in >95% of cases of primary biliary cholangitis, which usually causes fatigue, pruritus, hepatomegaly, and elevated alkaline phosphatase. This patient's systemic maculopapular rash and diffuse lymphadenopathy make syphilis more likely.

Educational objective:
Syphilis is caused by the spirochete *Treponema pallidum*. Confirmation of the diagnosis requires 2 forms of serologic testing to prevent false-positive results. Nontreponemal tests (eg, rapid plasma reagin, VDRL) evaluate for anticardiolipin antibodies (nonspecific); treponemal tests evaluate for antibodies targeted against *T pallidum*.

Microbiology	Infectious Diseases	Syphilis
Subject	System	Topic

Copyright © UWorld. All rights reserved.

Syphilis: diagnostic serology	
Nontreponemal	• Antibody to cardiolipin-cholesterol-lecithin antigen

Exhibit Display

Syphilis manifestations	
Primary	• Painless genital ulcer (chancre)
Secondary	• Diffuse rash (palms & soles) • Lymphadenopathy (epitrochlear) • Condyloma latum • Oral lesions • Hepatitis
Latent	• Asymptomatic
Tertiary	• CNS (tabes dorsalis, dementia) • Cardiovascular (aortic aneurysm/insufficiency) • Cutaneous (gummas)

CNS = central nervous system.

Add To New Card | Existing Card

This patient has fever, arth n
for secondary syphilis. Sy on
rely primarily on serologic

Nontreponemal serologi n or
flocculation (clumping) ind
release of lipids from cells
treponemal (eg, yaws, pin
lead to false-positive resul

Positive nontreponemal sc
absorption). Treponemal te
for antibody adherence us
syphilis.

(Choice A) Lyme disease and
a bull's-eye rash (not a dif
progresses.

(Choice B) Rheumatoid factor is an antibody that targets the Fc portion of IgG. Elevations are often seen in patients with rheumatoid arthritis and other autoimmune diseases.

A 24-year-old female presents to your office with burning urination, urgency and frequency. She is sexually active. Urine cultures show catalase-positive, gram-positive cocci. The organism responsible for this patient's symptoms is most likely to be:

- A. Coagulase positive
- B. Hemolytic
- C. Novobiocin resistant
- D. DNase positive
- E. Yellow pigment producer

Submit

A 24-year-old female presents to your office with burning urination, urgency and frequency. She is sexually active. Urine cultures show catalase-positive, gram-positive cocci. The organism responsible for this patient's symptoms is most likely to be:

- A. Coagulase positive (15%)
- B. Hemolytic (6%)
- ✓ C. Novobiocin resistant (72%)
- D. DNase positive (2%)
- E. Yellow pigment producer (4%)

Omitted
Correct answer
C

72%
Answered correctly

03 secs
Time Spent

02/03/2020
Last Updated

Explanation

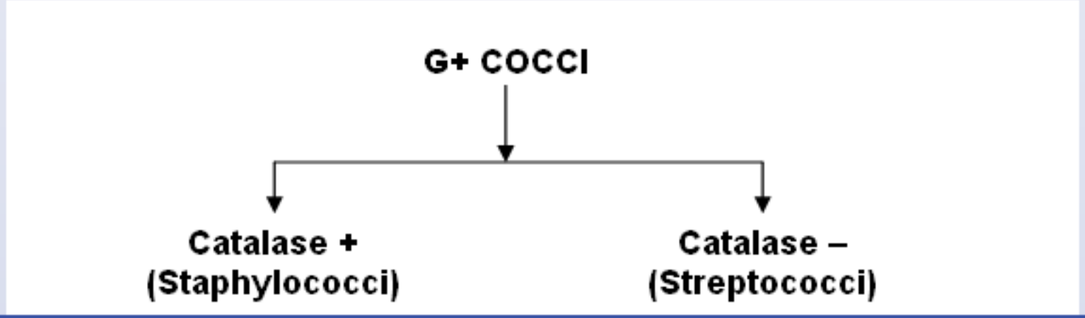

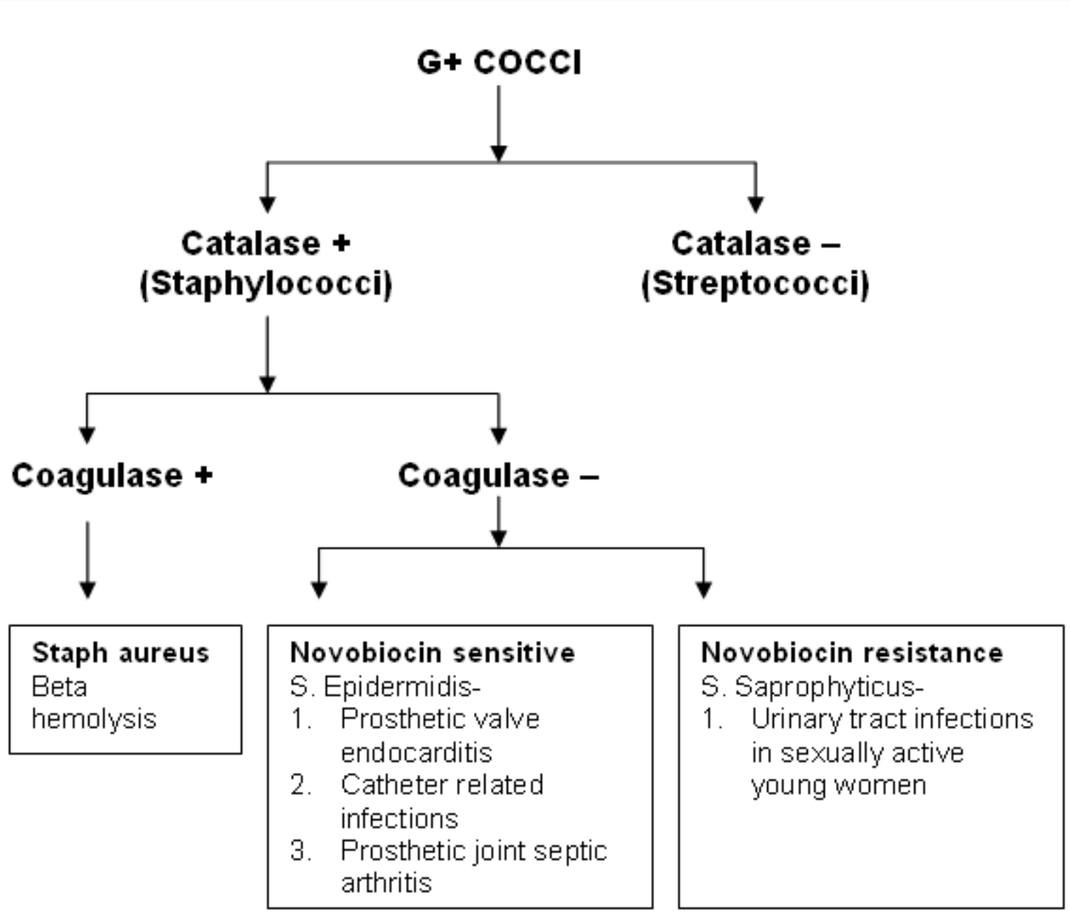

The Staphylococci are Gram-positive cocci that form clusters, pairs and, rarely, short chains. The catalase test (with 3% hydrogen peroxide) differentiates Streptococci (catalase-negative) from Staphylococci (catalase-positive). The ability to clot blood plasma (slide and tube coagulase tests) separates Staphylococci into two groups: the coagulase-positive Staphylococci, which constitutes the most pathogenic species *Staphylococcus aureus*, and coagulase-negative staphylococci (CNS), which constitutes *S. epidermidis*, *S. Saprophyticus*, *S. haemolyticus*, and 30+ other species. The coagulase-negative staphylococci exist as part of the normal flora on the skin and in the throat and nose, and only some

The Staphylococci are Gram-positive cocci that form clusters, pairs and, rarely, short chains. The catalase test (with 3% hydrogen peroxide) differentiates Streptococci (catalase-negative) from Staphylococci (catalase-positive). The ability to clot blood plasma (slide and tube coagulase tests) separates Staphylococci into two groups: the coagulase-positive Staphylococci, which constitutes the most pathogenic species *Staphylococcus aureus,* and coagulase-negative staphylococci (CNS), which constitutes *S. epidermidis*, *S. Saprophyticus*, *S. haemolyticus,* and *30+* other species. The coagulase-negative staphylococci exist as part of the normal flora on the skin and in the throat and nose, and only some species can cause infections.

S. saprophyticus is a common cause of urinary tract infection; it is responsible for almost half of all UTIs in sexually active young women. *S. saprophyticus* is resistant to novobiocin. When catalase-positive, coagulase-negative gram-positive cocci in clusters are isolated from urine specimens of the above group of patients, the laboratory performs a novobiocin test to distinguish this organism from other similar pathogens.

(Choice A) Coagulase positivity is a characteristic of S. aureus; this is how S. aureus is differentiated from the other species of Staphylococci that do not express coagulase.

(Choice B) Hemolysis is a typical feature of Streptococci (streptolysin O and streptolysin S) and Staphylococcus aureus (hemolysin). *S. saprophyticus* does not cause hemolysis.

(Choice D) DNase is produced by group A *streptococcus*. DNase degrades DNA in pus to facilitate spread of the organism. Anti DNase can be used as a laboratory test in patients who have had streptococcal infection followed by glomerulonephritis. DNase is not produced by *S. saprophyticus*.

(Choice E) Yellow pigment is produced by *Staphylococcus aureus*. *Staphylococcus aureus* usually does not cause urinary tract infections. If *S. aureus* is cultured from the urine you should suspect a metastatic infection from another location in the body (an abscess or infective endocarditis etc.)

Educational Objective:
S saprophyticus is responsible for almost half of all UTIs in sexually active young women. *Staphylococcus saprophyticus* belongs to coagulase negative staphylococci and is unique among these because it is resistant to novobiocin.

Microbiology	Infectious Diseases	Urinary tract infection
Subject	System	Topic

A 16-year-old girl comes to the office due to 2 days of a burning sensation with urination. She had sexual intercourse with her partner last week and used a condom for contraception. The patient says, "I always urinate right after sex." She has no vaginal discharge, and vital signs are normal. Examination shows suprapubic tenderness. Urinalysis reveals positive nitrites, positive leukocyte esterase, 50 white blood cells/hpf, and many bacteria. Urine β-hCG is negative. Which of the following is the most likely cause of this patient's infection?

- A. Ascending infection
- B. Hematogenous spread of infection
- C. Lymphatic spread of infection
- D. Poor genital hygiene
- E. Sexually transmitted infection

Submit

A 16-year-old girl comes to the office due to 2 days of a burning sensation with urination. She had sexual intercourse with her partner last week and used a condom for contraception. The patient says, "I always urinate right after sex." She has no vaginal discharge, and vital signs are normal. Examination shows suprapubic tenderness. Urinalysis reveals positive nitrites, positive leukocyte esterase, 50 white blood cells/hpf, and many bacteria. Urine β-hCG is negative. Which of the following is the most likely cause of this patient's infection?

- ✓ A. Ascending infection (83%)
- B. Hematogenous spread of infection (0%)
- C. Lymphatic spread of infection (0%)
- D. Poor genital hygiene (11%)
- E. Sexually transmitted infection (3%)

Omitted
Correct answer
A

83%
Answered correctly

02 secs
Time Spent

03/07/2020
Last Updated

Explanation

This patient's dysuria, suprapubic tenderness, and urinalysis abnormalities suggest **acute simple cystitis**. Women are at much greater risk than men for urinary tract infections (UTIs) because they have a shorter urethra lying in close proximity to the anus and vaginal introitus, which allows **enteric flora** (eg, *Escherichia coli*) to spread to the vaginal opening and subsequently **ascend through the urethra to the bladder**. The major risk factor in otherwise healthy young women is recent **sexual intercourse**. Although urinating after intercourse flushes bacteria from the lower urinary tract (thereby reducing UTI risk), patients may still develop a UTI.

(Choice B) Hematologic infections generally enter the urinary tract through the glomeruli and cause pyelonephritis. Although pyuria and

Explanation

This patient's dysuria, suprapubic tenderness, and urinalysis abnormalities suggest **acute simple cystitis**. Women are at much greater risk than men for urinary tract infections (UTIs) because they have a shorter urethra lying in close proximity to the anus and vaginal introitus, which allows **enteric flora** (eg, *Escherichia coli*) to spread to the vaginal opening and subsequently **ascend through the urethra to the bladder**. The major risk factor in otherwise healthy young women is recent **sexual intercourse**. Although urinating after intercourse flushes bacteria from the lower urinary tract (thereby reducing UTI risk), patients may still develop a UTI.

(Choice B) Hematologic infections generally enter the urinary tract through the glomeruli and cause pyelonephritis. Although pyuria and bacteriuria are usually present, most patients are systemically ill with fever, chills, and/or fatigue. Hematologic dissemination directly to the bladder is uncommon.

(Choice C) Lymphatic spread of infection is common in skin and soft tissue infections (eg, cellulitis) and is often marked by erythematous streaks on the skin. Lymphatic spread to the urinary tract system is uncommon.

(Choice D) Although poor genital hygiene can increase the risk that bacteria spread from the anus to the vaginal introitus, the primary mechanism of acute simple cystitis is the ascending spread of bacteria through the urethra to the bladder.

(Choice E) Sexually transmitted infections, particularly *Chlamydia trachomatis*, *Trichomonas vaginalis*, and *Neisseria gonorrhea*, often cause dysuria in women. However, these infections are frequently associated with vaginal discharge. In addition, suprapubic tenderness less common.

Educational objective:
Women are at high risk for urinary tract infections due to a shorter urethra that is close to the anus and vaginal introitus, which allows enteric pathogens to colonize the vagina and ascend to the bladder. Acute simple cystitis is generally marked by dysuria, urinary frequency/urgency, suprapubic tenderness, and pyuria/bacteriuria on urinalysis.

Microbiology	Infectious Diseases	Urinary tract infection
Subject	System	Topic

Copyright © UWorld. All rights reserved.

A 43-year-old man comes to the emergency department due to 2 weeks of intermittent fevers, malaise, and headaches. He has a history of HIV and has not been taking his antiretroviral drugs recently. Five years ago, the patient spent a year in jail. Temperature is 38.2 C (100.8 F). Cerebrospinal fluid (CSF) analysis shows markedly elevated protein and low glucose, and CSF cultures grow *Mycobacterium tuberculosis*. Resistance testing shows the following:

Rifampin	sensitive
Isoniazid	sensitive
Pyrazinamide	sensitive
Ethambutol	sensitive
Streptomycin	resistant
Moxifloxacin	sensitive

Which of the following best explains the resistance pattern seen in these bacteria?

- A. Altered structure of bacterial ribosomal proteins
- B. Altered structure of enzymes involved in DNA winding-unwinding
- C. Altered structure of enzymes involved in RNA synthesis
- D. Decreased activity of bacterial catalase-peroxidase
- E. Increased activity of enzymes involved in cell wall polysaccharide synthesis

Submit

A 43-year-old man comes to the emergency department due to 2 weeks of intermittent fevers, malaise, and headaches. He has a history of HIV and has not been taking his antiretroviral drugs recently. Five years ago, the patient spent a year in jail. Temperature is 38.2 C (100.8 F). Cerebrospinal fluid (CSF) analysis shows markedly elevated protein and low glucose, and CSF cultures grow *Mycobacterium tuberculosis*. Resistance testing shows the following:

Rifampin	sensitive
Isoniazid	sensitive
Pyrazinamide	sensitive
Ethambutol	sensitive
Streptomycin	resistant
Moxifloxacin	sensitive

Which of the following best explains the resistance pattern seen in these bacteria?

- ✓ A. Altered structure of bacterial ribosomal proteins (74%)
- B. Altered structure of enzymes involved in DNA winding-unwinding (3%)
- C. Altered structure of enzymes involved in RNA synthesis (10%)
- D. Decreased activity of bacterial catalase-peroxidase (3%)
- E. Increased activity of enzymes involved in cell wall polysaccharide synthesis (8%)

Omitted
Correct answer

74%
Answered correctly

02 secs
Time Spent

06/03/2020
Last Updated

Drugs for treatment of tuberculosis		
Drug	**Mechanism of action**	**Side effects**
(R)ifampin	Inhibition of bacterial DNA-dependent RNA polymerase	GI side effects, rash, red-orange body fluids, cytopenias
(I)soniazid	Inhibition of mycolic acid synthesis	Neurotoxicity (give vitamin B_6/pyridoxine), hepatotoxicity
(P)yrazinamide	Unclear	Hepatotoxicity, hyperuricemia
(E)thambutol	Inhibition of arabinosyl transferase (?)	Optic neuropathy

GI = gastrointestinal.

This patient with HIV has fever, headache, and central nervous system (eg, spinal fluid) culture growing ***Mycobacterium tuberculosis***, consistent with *M tuberculosis* meningitis. Initial management is best accomplished through combination therapy with isoniazid (INH), rifampin, pyrazinamide, and either an injectable aminoglycoside or a fluoroquinolone.

Streptomycin is one of the older drugs in the aminoglycoside family; therefore, bacterial resistance to this antibiotic is widespread, resulting in its current usage being limited mainly to the treatment of tuberculosis, plague, and tularemia. Like other aminoglycosides, streptomycin can be administered only parenterally. It works by interfering with the 16s rRNA of the bacterial **30S ribosomal subunit**, thereby preventing bacterial protein synthesis. Mutations of the genes that encode ribosomal proteins are responsible for aminoglycoside resistance because they lead to modifications in the ribosomal binding sites for these drugs. Other resistance mechanisms to aminoglycosides include aminoglycoside-modifying enzymes (eg, transferases) and mutated porins.

(Choice B) Structural alteration of enzymes involved in DNA winding-unwinding is the means by which many microorganisms become resistant to fluoroquinolone antibiotics. Fluoroquinolones inhibit the bacterial enzymes DNA gyrase (topoisomerase II) and topoisomerase IV.

(Choice C) Structural alteration of enzymes involved in RNA synthesis is the mechanism through which organisms become resistant to rifampin.

This patient with HIV has fever, headache, and central nervous system (eg, spinal fluid) culture growing ***Mycobacterium tuberculosis***, consistent with *M tuberculosis* meningitis. Initial management is best accomplished through combination therapy with isoniazid (INH), rifampin, pyrazinamide, and either an injectable aminoglycoside or a fluoroquinolone.

Streptomycin is one of the older drugs in the aminoglycoside family; therefore, bacterial resistance to this antibiotic is widespread, resulting in its current usage being limited mainly to the treatment of tuberculosis, plague, and tularemia. Like other aminoglycosides, streptomycin can be administered only parenterally. It works by interfering with the 16s rRNA of the bacterial **30S ribosomal subunit**, thereby preventing bacterial protein synthesis. Mutations of the genes that encode ribosomal proteins are responsible for aminoglycoside resistance because they lead to modifications in the ribosomal binding sites for these drugs. Other resistance mechanisms to aminoglycosides include aminoglycoside-modifying enzymes (eg, transferases) and mutated porins.

(Choice B) Structural alteration of enzymes involved in DNA winding-unwinding is the means by which many microorganisms become resistant to fluoroquinolone antibiotics. Fluoroquinolones inhibit the bacterial enzymes DNA gyrase (topoisomerase II) and topoisomerase IV.

(Choice C) Structural alteration of enzymes involved in RNA synthesis is the mechanism through which organisms become resistant to rifampin. Rifampin inhibits the bacterial DNA-dependent RNA polymerase, thereby preventing the transcription of DNA into mRNA.

(Choice D) Decreased activity of bacterial catalase-peroxidase is a mechanism of mycobacterial resistance to INH. Mycobacterial catalase-peroxidase is required for the initial enzymatic conversion of INH to its active metabolite within the mycobacterial cells; without this enzyme, INH is unable to inhibit mycobacterial mycolic acid synthesis.

(Choice E) Increased activity of enzymes involved in cell wall polysaccharide synthesis is the means by which mycobacteria develop resistance to ethambutol. Ethambutol interferes specifically with mycobacterial peptidoglycan cell wall synthesis, possibly through inhibition of arabinosyl transferase. This drug is ineffective against organisms other than mycobacteria.

Educational objective:

- The aminoglycoside streptomycin inhibits protein synthesis by inactivating the 30S (small) ribosomal subunit.
- Decreased activity of bacterial catalase-peroxidase is a mechanism of mycobacterial resistance to isoniazid.
- Structural alteration of enzymes involved in RNA synthesis (DNA-dependent RNA polymerase) is the mechanism through which organisms become resistant to rifampin.

current usage being limited mainly to the treatment of tuberculosis, plague, and tularemia. Like other aminoglycosides, streptomycin can be administered only parenterally. It works by interfering with the 16s rRNA of the bacterial **30S ribosomal subunit**, thereby preventing bacterial protein synthesis. Mutations of the genes that encode ribosomal proteins are responsible for aminoglycoside resistance because they lead to modifications in the ribosomal binding sites for these drugs. Other resistance mechanisms to aminoglycosides include aminoglycoside-modifying enzymes (eg, transferases) and mutated porins.

(Choice B) Structural alteration of enzymes involved in DNA winding-unwinding is the means by which many microorganisms become resistant to fluoroquinolone antibiotics. Fluoroquinolones inhibit the bacterial enzymes DNA gyrase (topoisomerase II) and topoisomerase IV.

(Choice C) Structural alteration of enzymes involved in RNA synthesis is the mechanism through which organisms become resistant to rifampin. Rifampin inhibits the bacterial DNA-dependent RNA polymerase, thereby preventing the transcription of DNA into mRNA.

(Choice D) Decreased activity of bacterial catalase-peroxidase is a mechanism of mycobacterial resistance to INH. Mycobacterial catalase-peroxidase is required for the initial enzymatic conversion of INH to its active metabolite within the mycobacterial cells; without this enzyme, INH is unable to inhibit mycobacterial mycolic acid synthesis.

(Choice E) Increased activity of enzymes involved in cell wall polysaccharide synthesis is the means by which mycobacteria develop resistance to ethambutol. Ethambutol interferes specifically with mycobacterial peptidoglycan cell wall synthesis, possibly through inhibition of arabinosyl transferase. This drug is ineffective against organisms other than mycobacteria.

Educational objective:

- The aminoglycoside streptomycin inhibits protein synthesis by inactivating the 30S (small) ribosomal subunit.
- Decreased activity of bacterial catalase-peroxidase is a mechanism of mycobacterial resistance to isoniazid.
- Structural alteration of enzymes involved in RNA synthesis (DNA-dependent RNA polymerase) is the mechanism through which organisms become resistant to rifampin.

Microbiology	Infectious Diseases	Antibiotic resistance
Subject	System	Topic

Copyright © UWorld. All rights reserved.

A 4-year-old boy is brought to the office due to skin lesions on his chin for the past 2 days. Temperature is 36.1 C (97 F). The patient is well-appearing. There are mildly tender perioral papules and pustules, some of which appear to have broken down and are covered with amber-colored crusting. A wound culture is taken, and Gram stain shows gram-positive cocci in chains. Which of the following symptoms would be most likely to develop as a potential complication of this patient's infection?

- A. Ascending weakness
- B. Facial puffiness and dark urine
- C. Fatigue and heart murmur
- D. Joint pain and eye redness
- E. Unilateral facial drooping

Submit

A 4-year-old boy is brought to the office due to skin lesions on his chin for the past 2 days. Temperature is 36.1 C (97 F). The patient is well-appearing. There are mildly tender perioral papules and pustules, some of which appear to have broken down and are covered with amber-colored crusting. A wound culture is taken, and Gram stain shows gram-positive cocci in chains. Which of the following symptoms would be most likely to develop as a potential complication of this patient's infection?

- A. Ascending weakness (0%)
- ✓ B. Facial puffiness and dark urine (77%)
- C. Fatigue and heart murmur (15%)
- D. Joint pain and eye redness (5%)
- E. Unilateral facial drooping (1%)

Omitted
Correct answer
B

77%
Answered correctly

02 secs
Time Spent

06/23/2020
Last Updated

Explanation

Nonbullous impetigo	
Microbiology	• *Staphylococcus aureus* (most common) • Group A *Streptococcus* (*S pyogenes*)
Clinical features	• Papules & pustules with honey-crusted lesions • May be painful or itchy

Nonbullous impetigo	
Microbiology	• *Staphylococcus aureus* (most common) • Group A *Streptococcus* (*S pyogenes*)
Clinical features	• Papules & pustules with honey-crusted lesions • May be painful or itchy • Most commonly involves face or extremities in young children
Treatment	• Topical antibiotics (eg, mupirocin) if localized • Oral antibiotics (eg, cephalexin) if extensive
Complications	• Poststreptococcal glomerulonephritis

This child has **impetigo**, a superficial bacterial infection that most commonly develops on the face or extremities in children. Patients usually develop mildly itchy or painful erythematous papules and pustules that later erupt, forming a honey-colored crusting. The most common pathogen is *Staphylococcus aureus* followed by **group A *Streptococcus*** (GAS, *S pyogenes*).

Treatment of localized impetigo is with topical antibiotics (eg, mupirocin), and most patients have no long-term sequelae. However, a minority of patients may develop **poststreptococcal glomerulonephritis** (PSGN) several weeks after impetigo caused by GAS (as indicated by this patient's Gram stain showing **gram-positive cocci in chains**). Renal damage is caused by immune complex deposition as well as complement activation, leading to a massive inflammatory response that damages the glomerular basement membrane.

Symptoms of PSGN range from asymptomatic, microscopic hematuria to gross **hematuria** and nephrotic-range **proteinuria**. In addition to tea- or cola-colored urine, patients may develop **periorbital/facial swelling**, generalized edema, and hypertension. Laboratory evaluation typically reveals elevated creatinine and decreased complement C3 level.

(Choice A) Ascending weakness is a classic feature of Guillain-Barre syndrome, which may be preceded by an upper respiratory or gastrointestinal (eg, *Campylobacter jejuni*) infection. GAS disease is not associated with this condition.

(Choice C) Fatigue and a new heart murmur due to carditis can be manifestations of acute rheumatic fever, a potential poststreptococcal

This child has **impetigo**, a superficial bacterial infection that most commonly develops on the face or extremities in children. Patients usually develop mildly itchy or painful erythematous papules and pustules that later erupt, forming a honey-colored crusting. The most common pathogen is *Staphylococcus aureus* followed by **group A *Streptococcus*** (GAS, *S pyogenes*).

Treatment of localized impetigo is with topical antibiotics (eg, mupirocin), and most patients have no long-term sequelae. However, a minority of patients may develop **poststreptococcal glomerulonephritis** (PSGN) several weeks after impetigo caused by GAS (as indicated by this patient's Gram stain showing **gram-positive cocci in chains**). Renal damage is caused by immune complex deposition as well as complement activation, leading to a massive inflammatory response that damages the glomerular basement membrane.

Symptoms of PSGN range from asymptomatic, microscopic hematuria to gross **hematuria** and nephrotic-range **proteinuria**. In addition to tea- or cola-colored urine, patients may develop **periorbital/facial swelling**, generalized edema, and hypertension. Laboratory evaluation typically reveals elevated creatinine and decreased complement C3 level.

(Choice A) Ascending weakness is a classic feature of Guillain-Barre syndrome, which may be preceded by an upper respiratory or gastrointestinal (eg, *Campylobacter jejuni*) infection. GAS disease is not associated with this condition.

(Choice C) Fatigue and a new heart murmur due to carditis can be manifestations of acute rheumatic fever, a potential poststreptococcal sequelae associated with GAS pharyngitis. This disease is not associated with impetigo in developed regions, although this relationship is less clear in some parts of the developing world.

(Choice D) Eye redness (due to conjunctivitis or anterior uveitis) and joint pain may be seen in reactive arthritis, which typically occurs following a diarrheal (eg, Salmonella) or genitourinary (eg, chlamydial) infection, not impetigo.

(Choice E) Unilateral facial drooping due to a facial nerve palsy (ie, Bell palsy) is often associated with herpes simplex virus infection, not impetigo.

Educational objective:
Poststreptococcal glomerulonephritis is a potential complication of group A streptococcal infection (eg, impetigo, pharyngitis). Symptoms include proteinuria (often associated with periorbital or generalized edema) and hematuria. Acute rheumatic fever is a postinfectious sequelae of streptococcal pharyngitis only, not impetigo.

References

Symptoms of PSGN range from asymptomatic, microscopic hematuria to gross **hematuria** and nephrotic-range **proteinuria**. In addition to tea- or cola-colored urine, patients may develop **periorbital/facial swelling**, generalized edema, and hypertension. Laboratory evaluation typically reveals elevated creatinine and decreased complement C3 level.

(Choice A) Ascending weakness is a classic feature of Guillain-Barre syndrome, which may be preceded by an upper respiratory or gastrointestinal (eg, *Campylobacter jejuni*) infection. GAS disease is not associated with this condition.

(Choice C) Fatigue and a new heart murmur due to carditis can be manifestations of acute rheumatic fever, a potential poststreptococcal sequelae associated with GAS pharyngitis. This disease is not associated with impetigo in developed regions, although this relationship is less clear in some parts of the developing world.

(Choice D) Eye redness (due to conjunctivitis or anterior uveitis) and joint pain may be seen in reactive arthritis, which typically occurs following a diarrheal (eg, Salmonella) or genitourinary (eg, chlamydial) infection, not impetigo.

(Choice E) Unilateral facial drooping due to a facial nerve palsy (ie, Bell palsy) is often associated with herpes simplex virus infection, not impetigo.

Educational objective:
Poststreptococcal glomerulonephritis is a potential complication of group A streptococcal infection (eg, impetigo, pharyngitis). Symptoms include proteinuria (often associated with periorbital or generalized edema) and hematuria. Acute rheumatic fever is a postinfectious sequelae of streptococcal pharyngitis only, not impetigo.

References

- Impetigo: diagnosis and treatment.
- Poststreptococcal glomerulonephritis.

Microbiology	Infectious Diseases	Skin and soft tissue infections
Subject	System	Topic

Copyright © UWorld. All rights reserved.

Clinical features	• May be painful or itchy

Exhibit Display

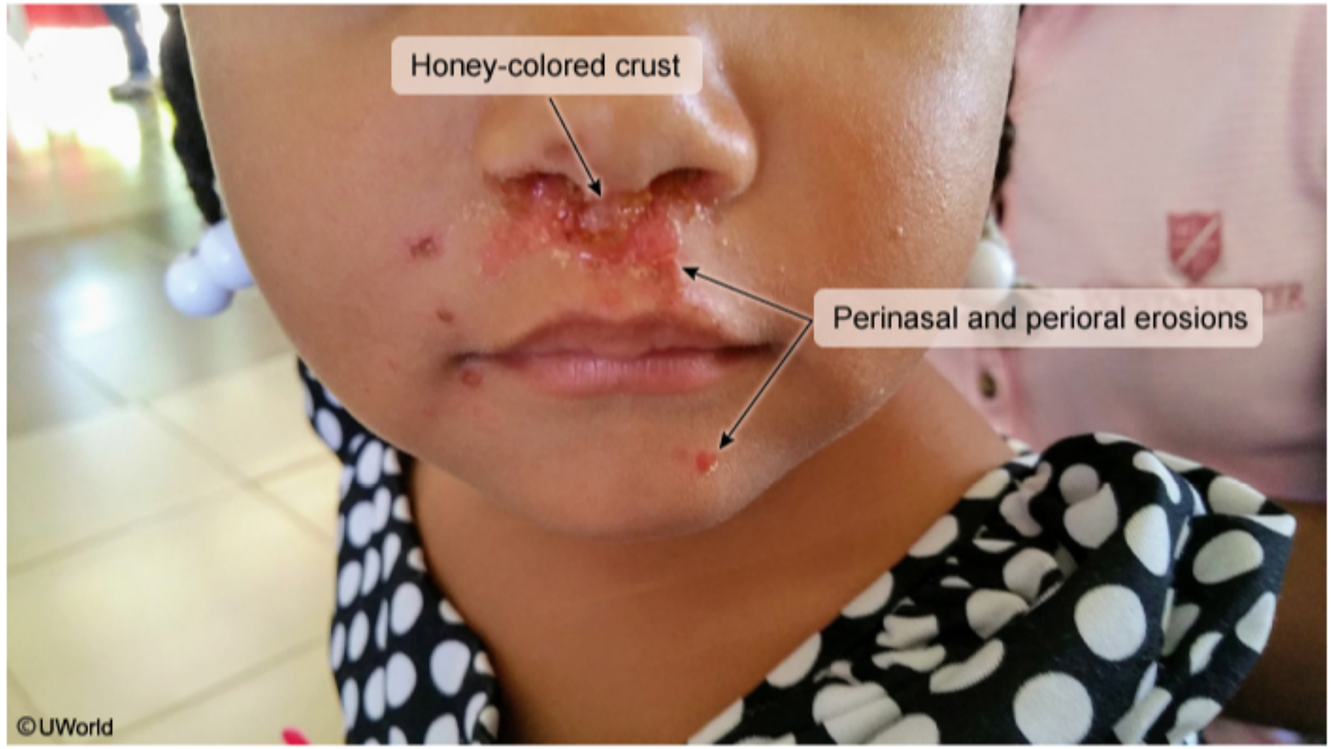

Zoom In | Zoom Out | Reset | Add To New Card | Existing Card

impetigo.

Symptoms of PSGN range from asymptomatic, microscopic hematuria to gross **hematuria** and nephrotic-range **proteinuria**. In addition to tea- or

Exhibit Display

Peripheral facial palsy

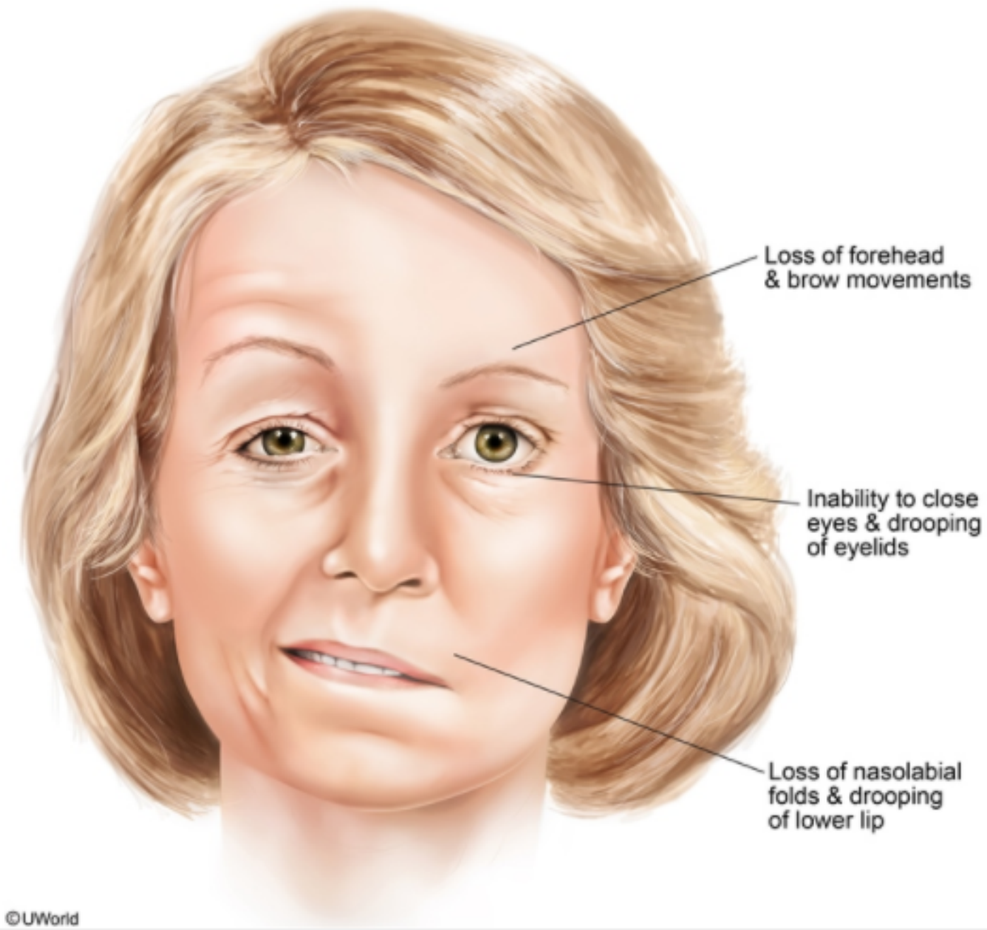

Zoom In | Zoom Out | Reset | Add To New Card | Existing Card